EUS-Guided Biliary Access

Dr. Mohammad Bagheri

DDRI, TUMS

- EUS-guided pancreaticobiliary drainage is emerging as an alternative to percutaneous or surgical drainage in patients in whom ERCP fails to access the ducts.

- ***EUS-guided pancreaticobiliary drainage is likely the most technically challenging procedure among EUS and ERCP, it should only be performed at tertiary referral centers with experienced endosonographers and available pancreaticobiliary interventional radiologists and surgeons.***

Indications

- Malignant biliary obstruction (e.g., pancreatic carcinoma or cholangiocarcinoma)
- 2. Benign biliary obstruction (e.g., inflammatory stricture, stones, congenital ductal anomalies).

Equipment and Technical Considerations

- Equipment selection
- ***dilating balloon,Cystotome***,needle knife for tract dilation.
- EUS with a therapeutic channel linear array echoendoscope.
- FNA needles: Use of a larger caliber needle offers the ability to use a larger gauge guidewire that may facilitate traversal of stenotic strictures and facilitate passage of other accessories.

Appearance of the cautery-tipped stent delivery system for the lumen-apposing stent

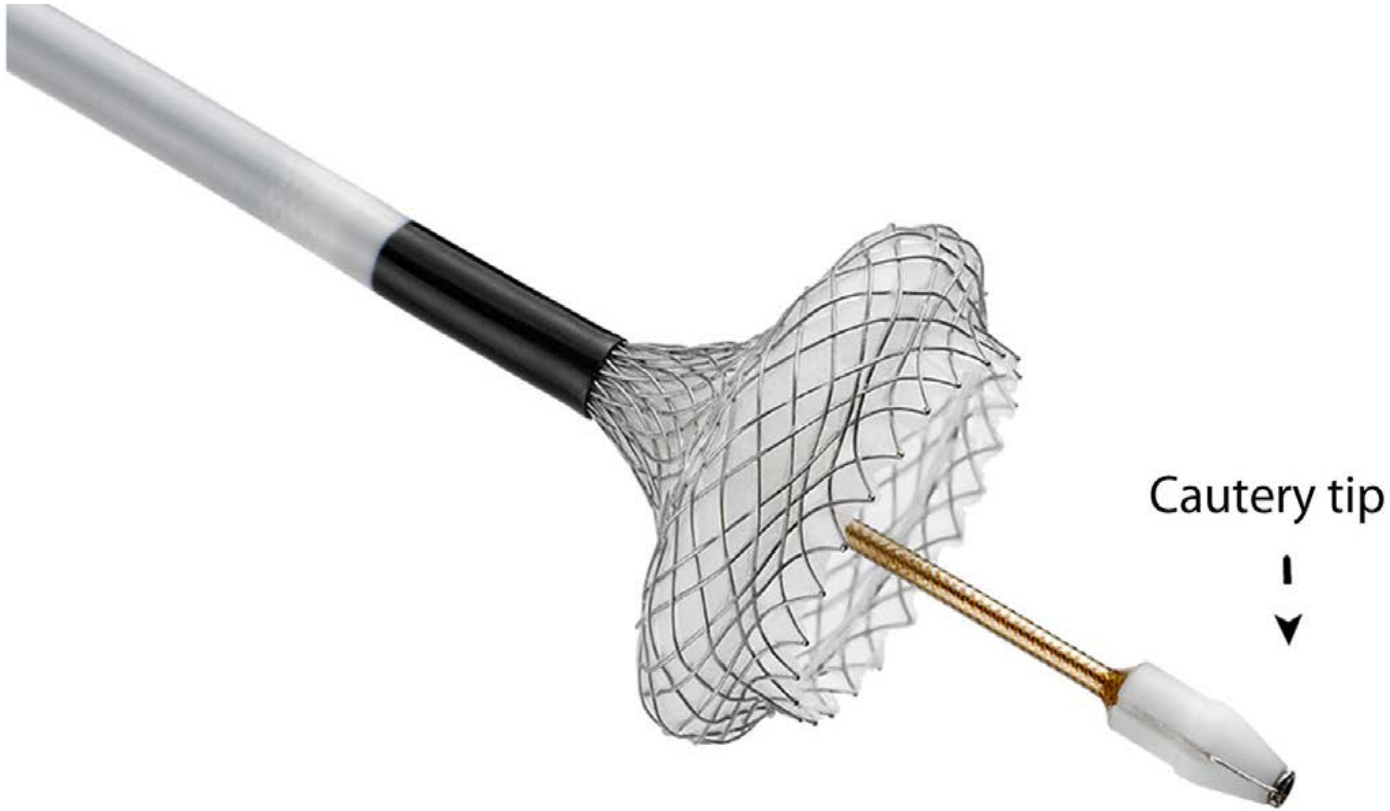

A, Steerable access system for EUS-guided biliary drainage. B, Sharp stylet. C, Upon stylet removal, cannula tip assumes a predetermined curvature.



- Beacon EUS Access System; Covidien/Medtronic, Inc.
- G=18.5-gauge
- (90 degree or 135 degree)
- fully rotatable



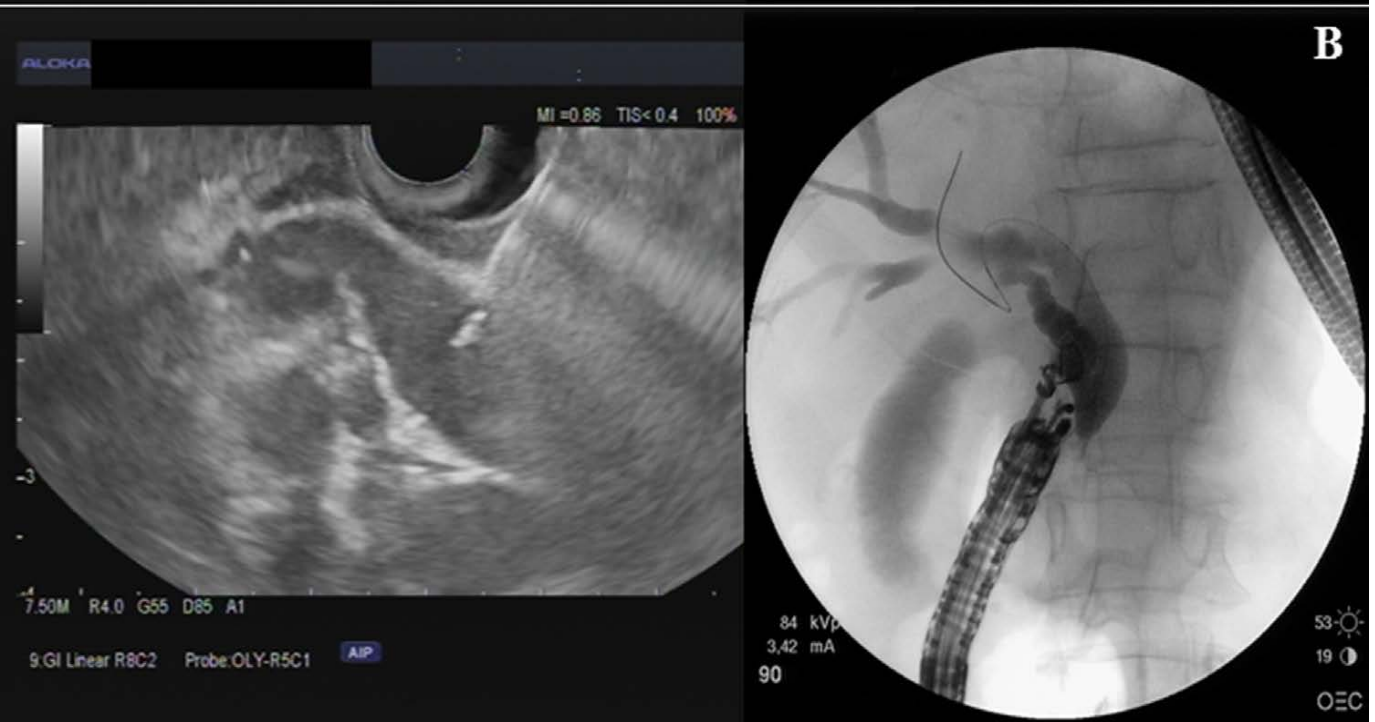

- Transgastric EUS-BD (A)
- transduodenal EUS-BD (B)

Rendezvous Access

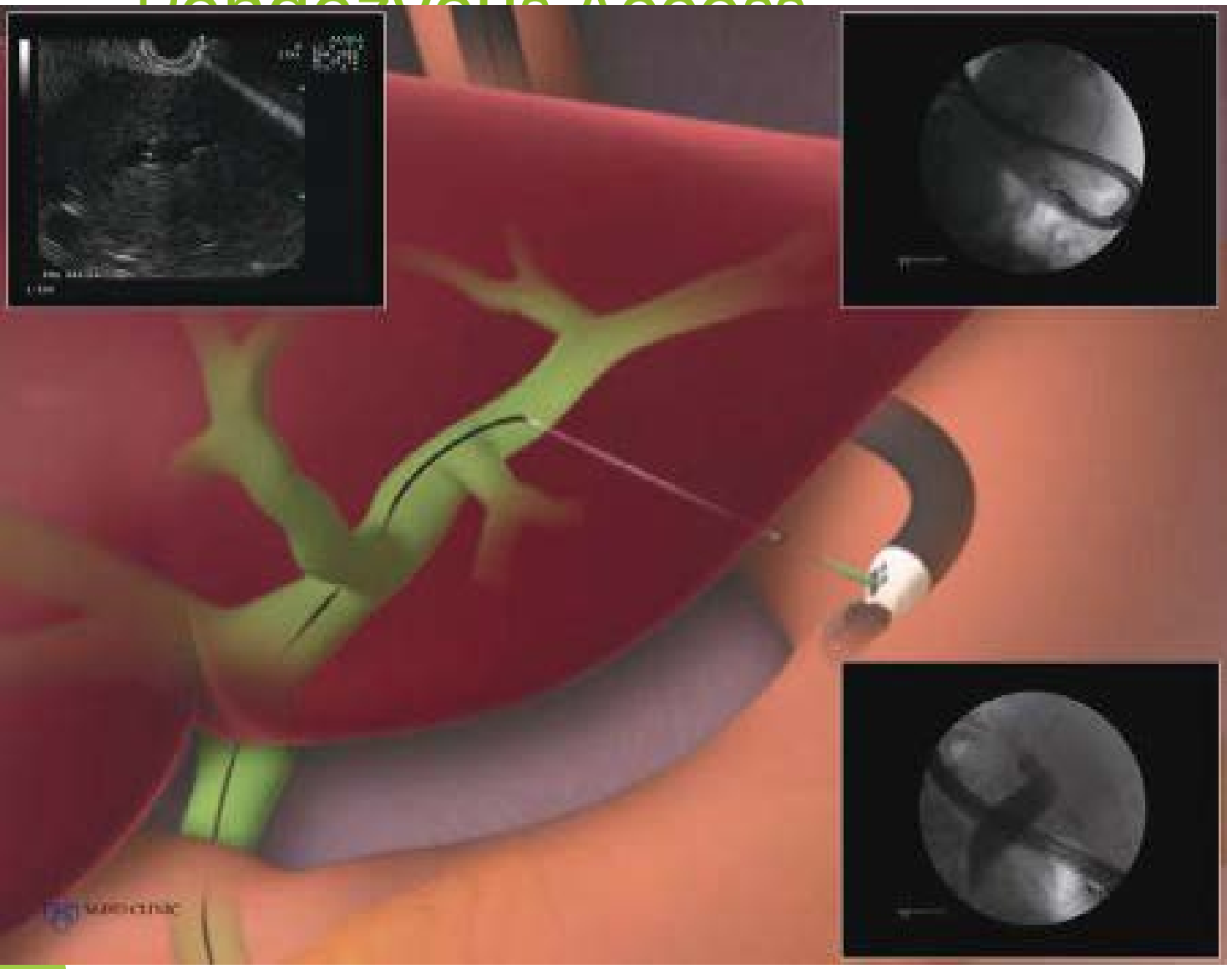

- The typical site of instrument positioning with needle insertion and wire placement in the bile duct as accessed via a left intrahepatic bile duct branch.
- EUS demonstrates the typical orientation of a desired intrahepatic bile duct with needle insertion.
- Fluoroscopy reveals the ideal scope position with resulting cholangiography and initial wire insertion.

Trans-gastric puncture of the left hepatic system, with contrast injection and chola



Guidewire advancement through the transgastric puncture until it crosses the papilla.



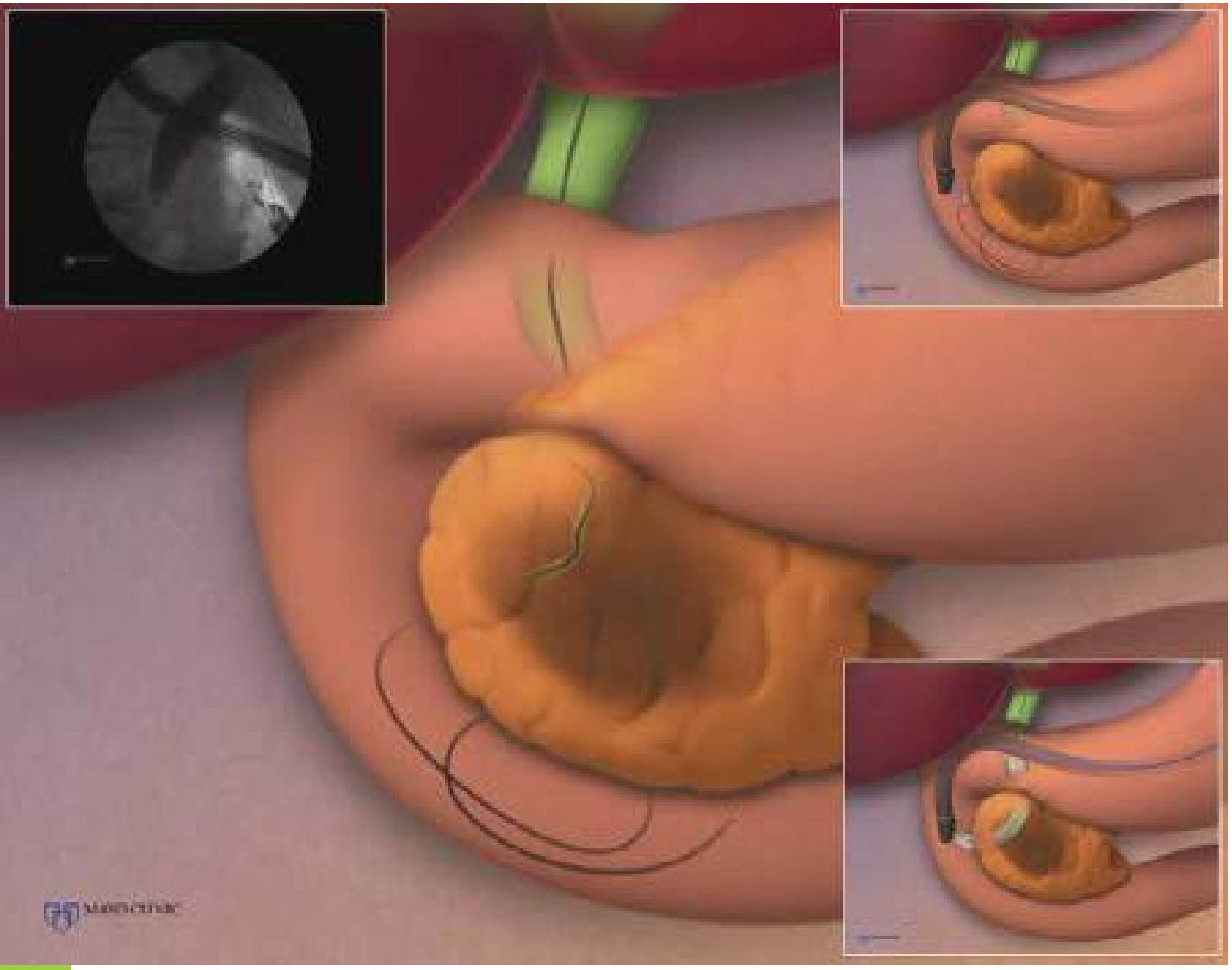

- The guidewire is passed through the site of obstruction, into the duodenum and coiled in the small bowel as demonstrated in the artwork and fluoroscopic image.
- The rendezvous portion of the examination follows with guidewire retrieval using a biopsy cable or snare with dilatation if required.

Transduodenal puncture with antegrade wire advancement until it crosses the papilla.



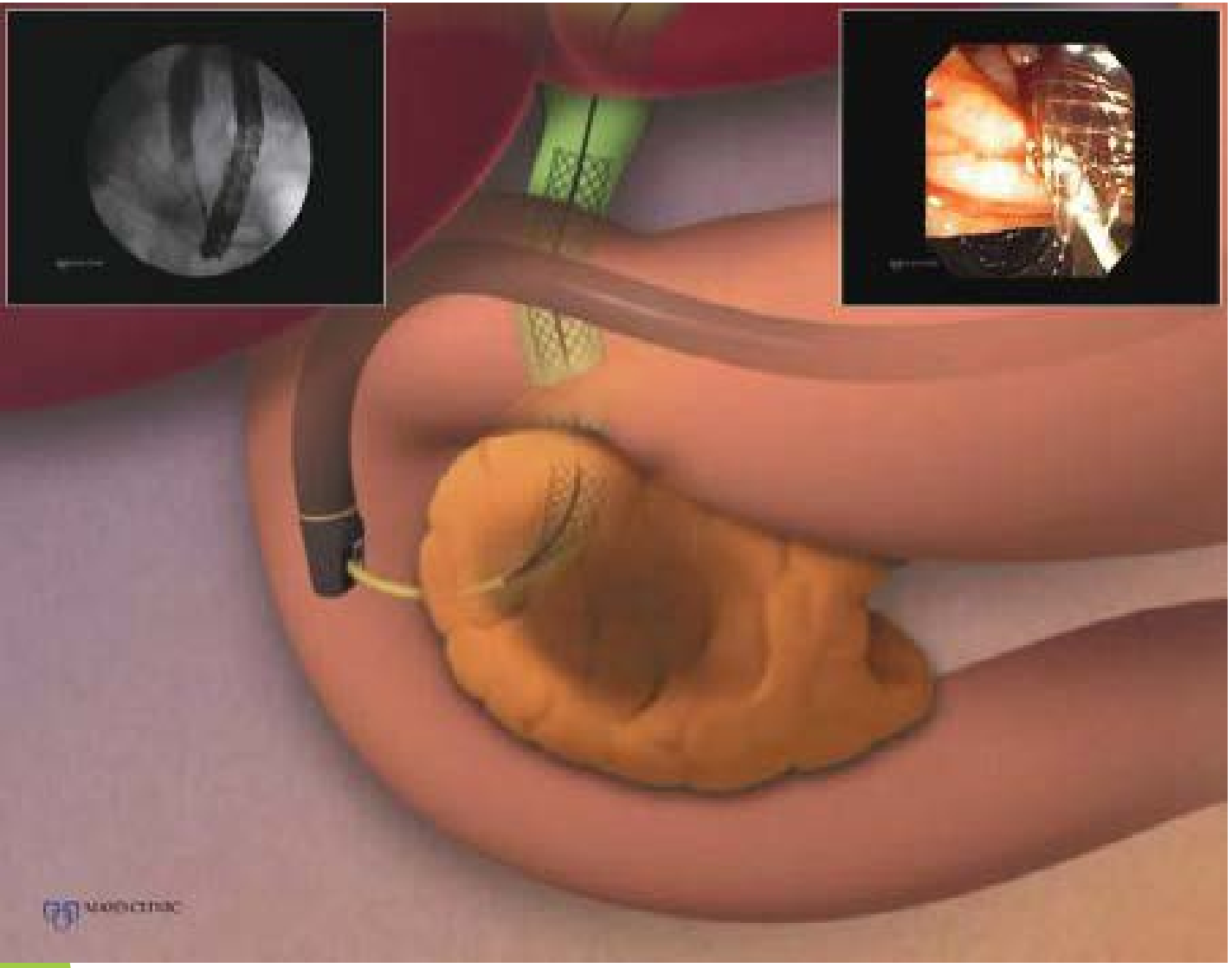

- A stent may then be placed in a retrograde fashion using standard techniques.

Rendezvous technique. The wire is retrieved from the duodenum and a stent isinserted in a retrograde manner.



Biliary rendezvous. EUS image shows curved access system tip (arrows) within the bile duct.
Inset shows cholangiogram and selective wire advancement antegrade acr

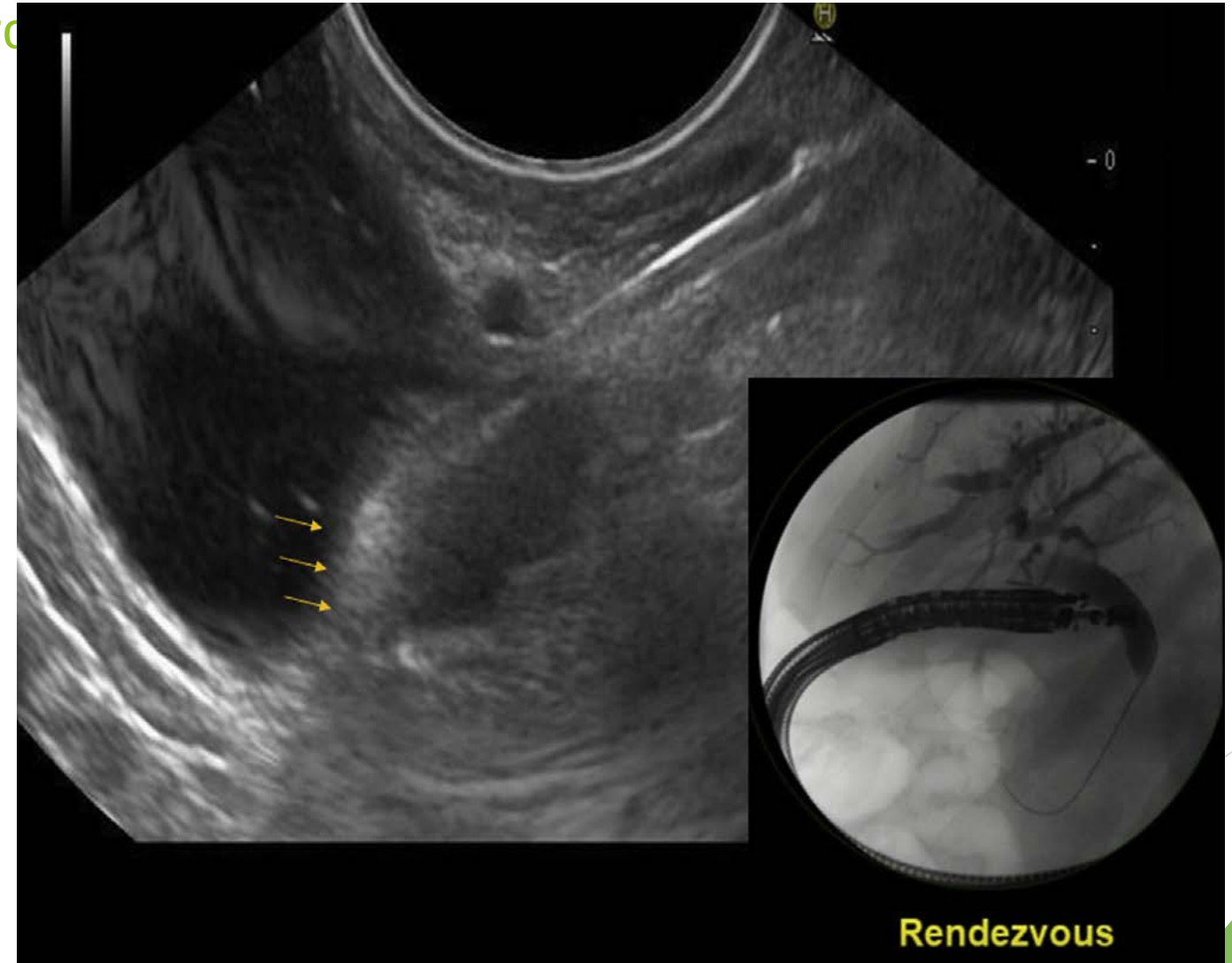

Intrahepatic Approach:
Hepatogastrostomy

- The echoendoscope must be positioned within the proximal stomach (cardia, fundus, or proximal body) and oriented along the lesser curve or more posterior position.
- the least distance between the transducer and a left intrahepatic bile duct branch
- Once the needle is advanced to the target duct, bile should be aspirated to confirm access and contrast is then injected to fluoroscopically delineate the biliary anatomy.
- Under fluoroscopic guidance, a guidewire is advanced through the FNA needle.
- Tract dilatation is required to include the gastric wall, hepatic parenchyma, and intrahepatic bile duct wall.

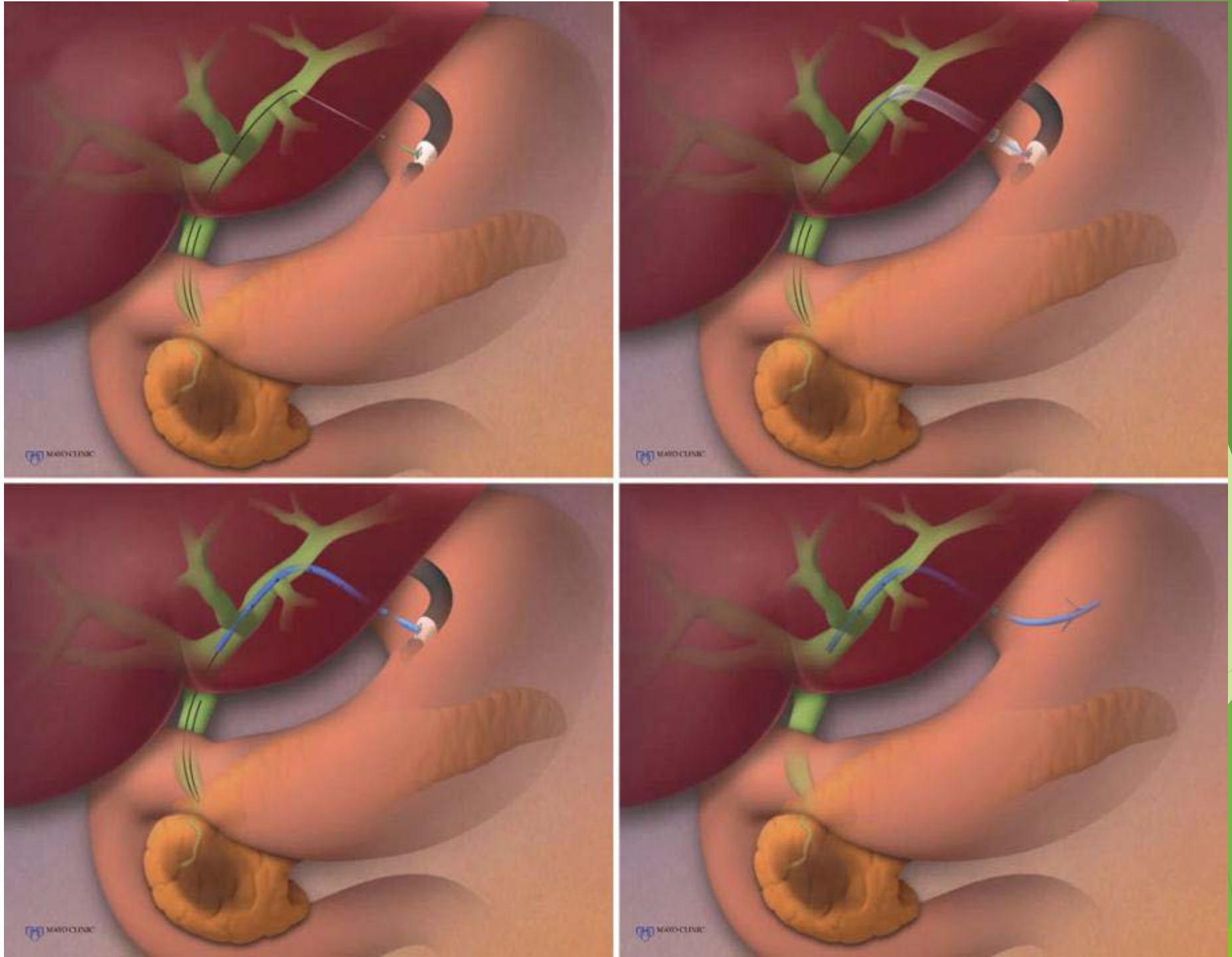

Guidewire advancement until multiple loops are seen in the intestinal tract, followed by balloon dilation.

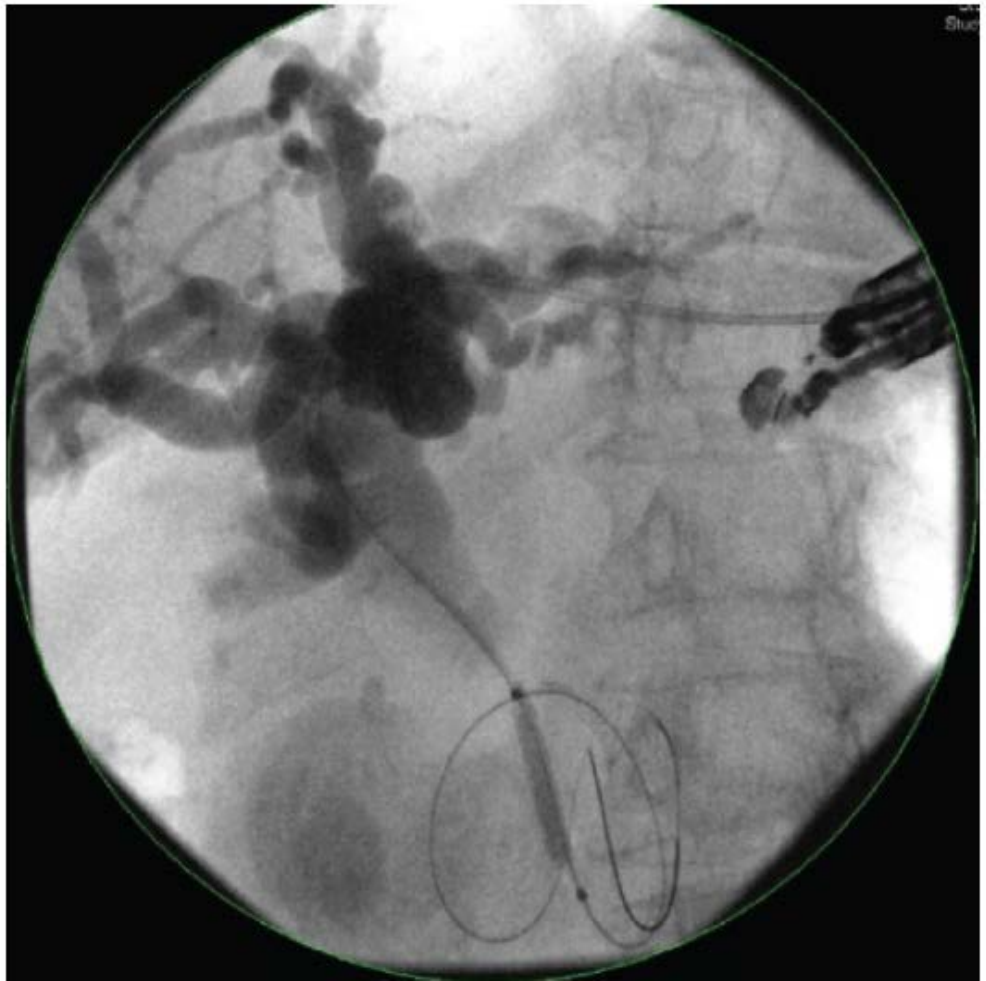

Balloon dilation at the level of the gastrohepatic fistula

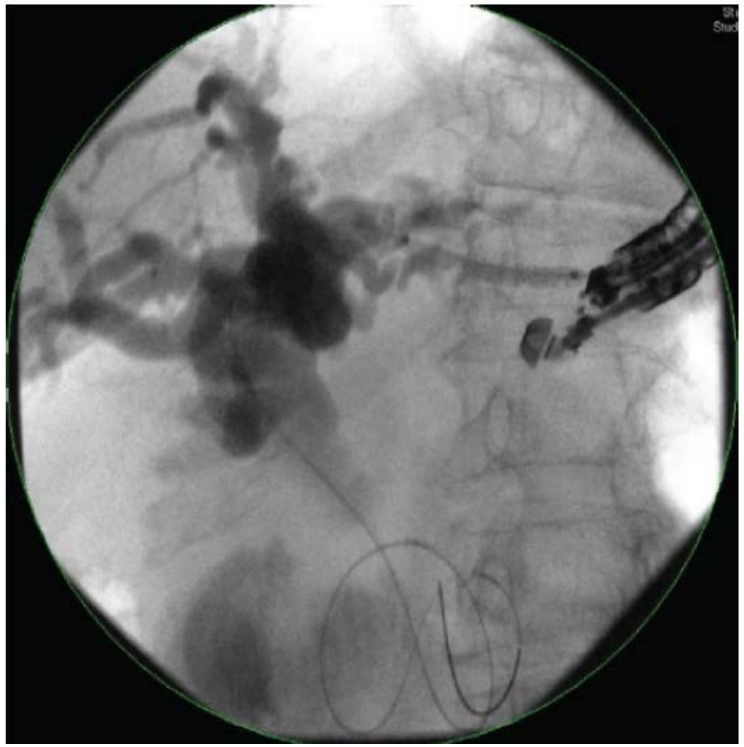

Bruching of the common bile duct stricture.

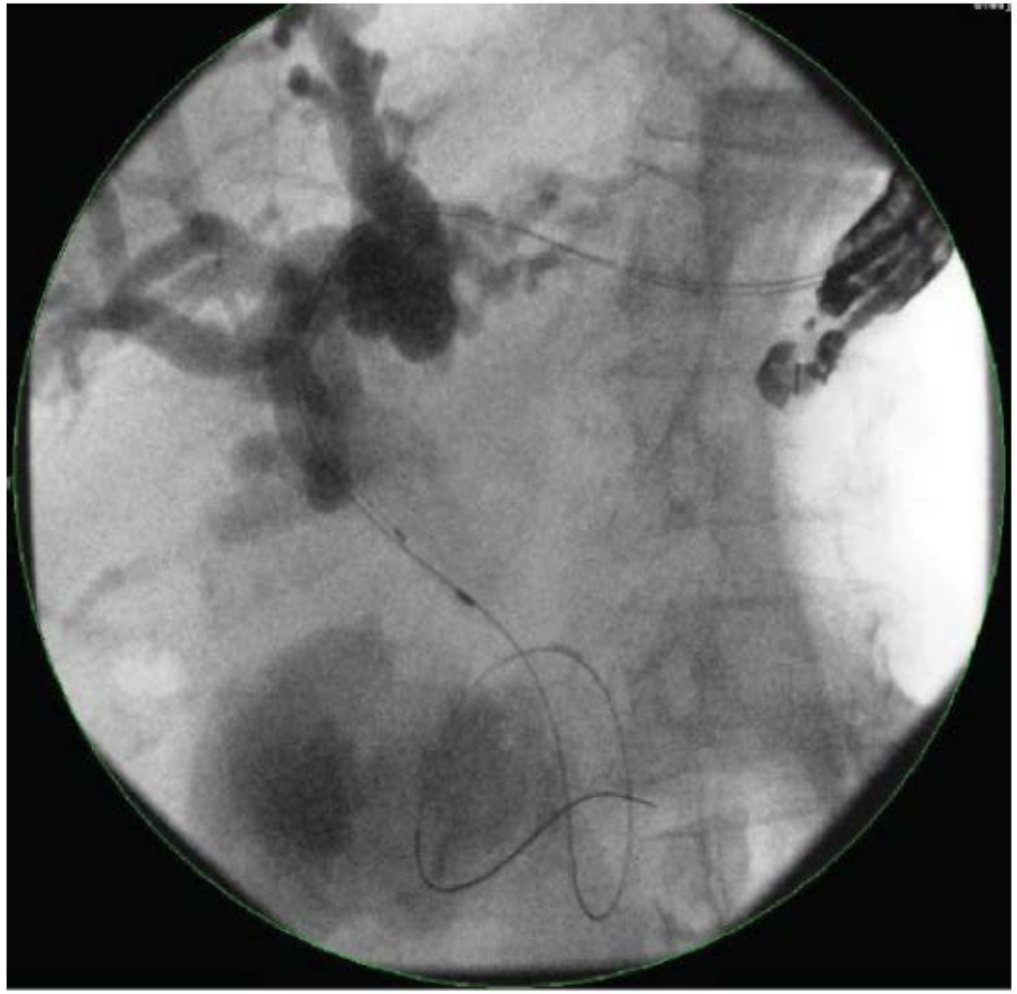

Antegrade, transpapillary common bile duct deployment of a fully covered metal stent.



Hepaticogastrostomy. Curved access system tip (arrows) within the dilated left intrahepatic bile duct.

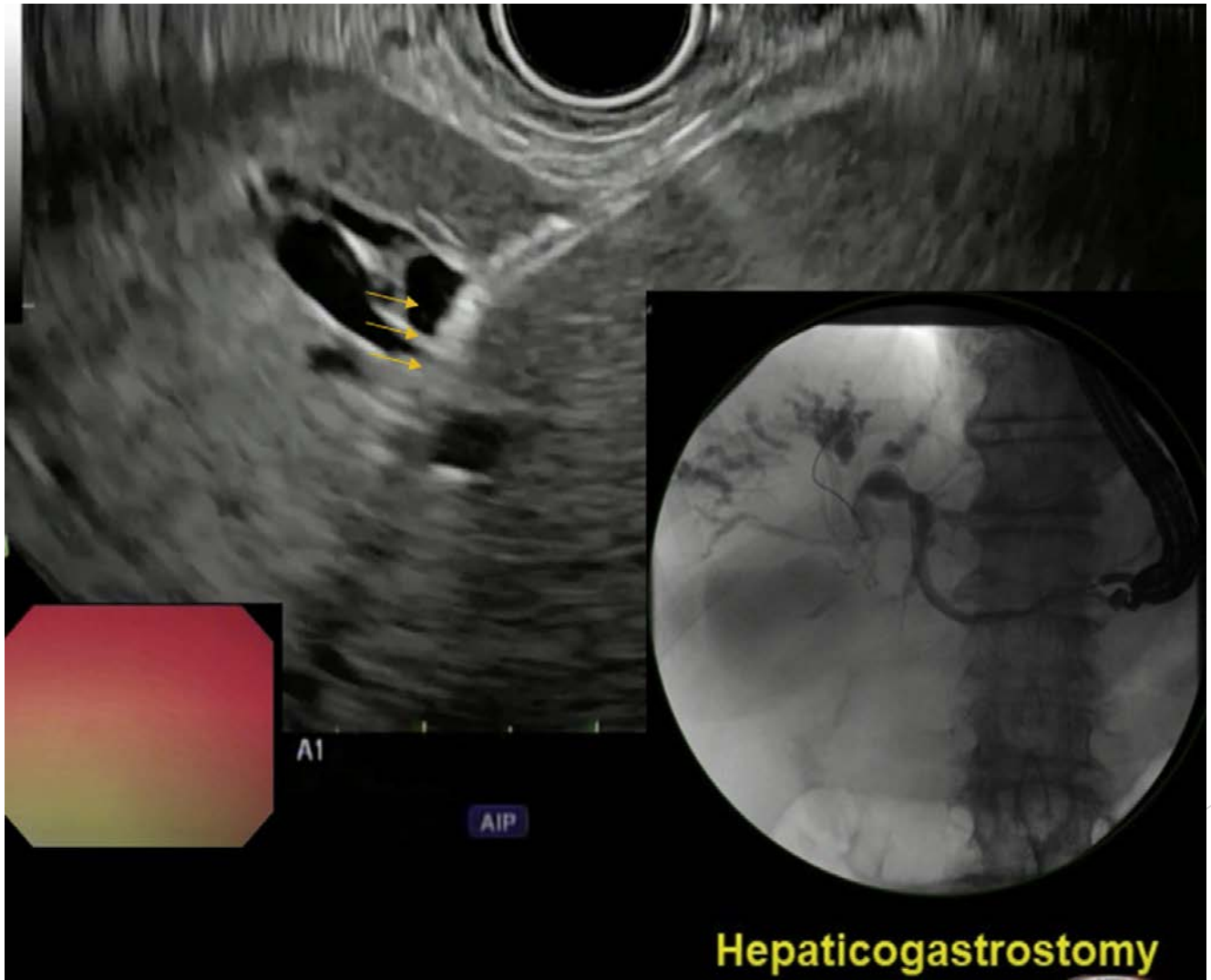

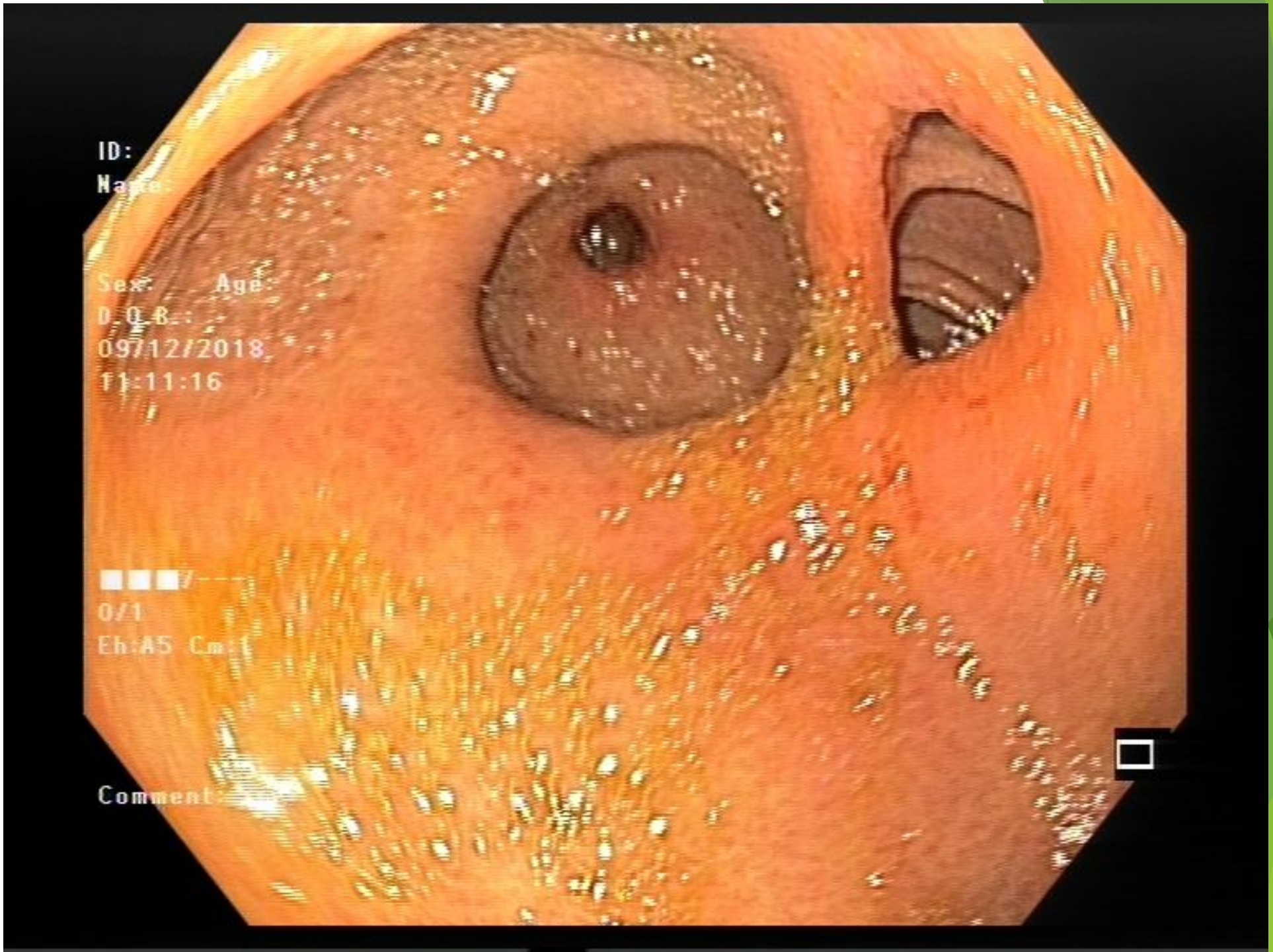
ID:
Sex: Age:
D.O.B.:
09/12/2018
11:11:16
0/1
Comment:


HITACHI
Shariati Hos.
Endoscope
'18/12/04 22:39:14
P:100% MI<0.4 TIS<0.4
+7.46
-7.46
cm/s
0
1
2
3
4
FR:23 BG:18 DR:65 CG:32 CF:M
EG-3870UTK T:10-3MHz 7.5MHz 1k/5.0MHz

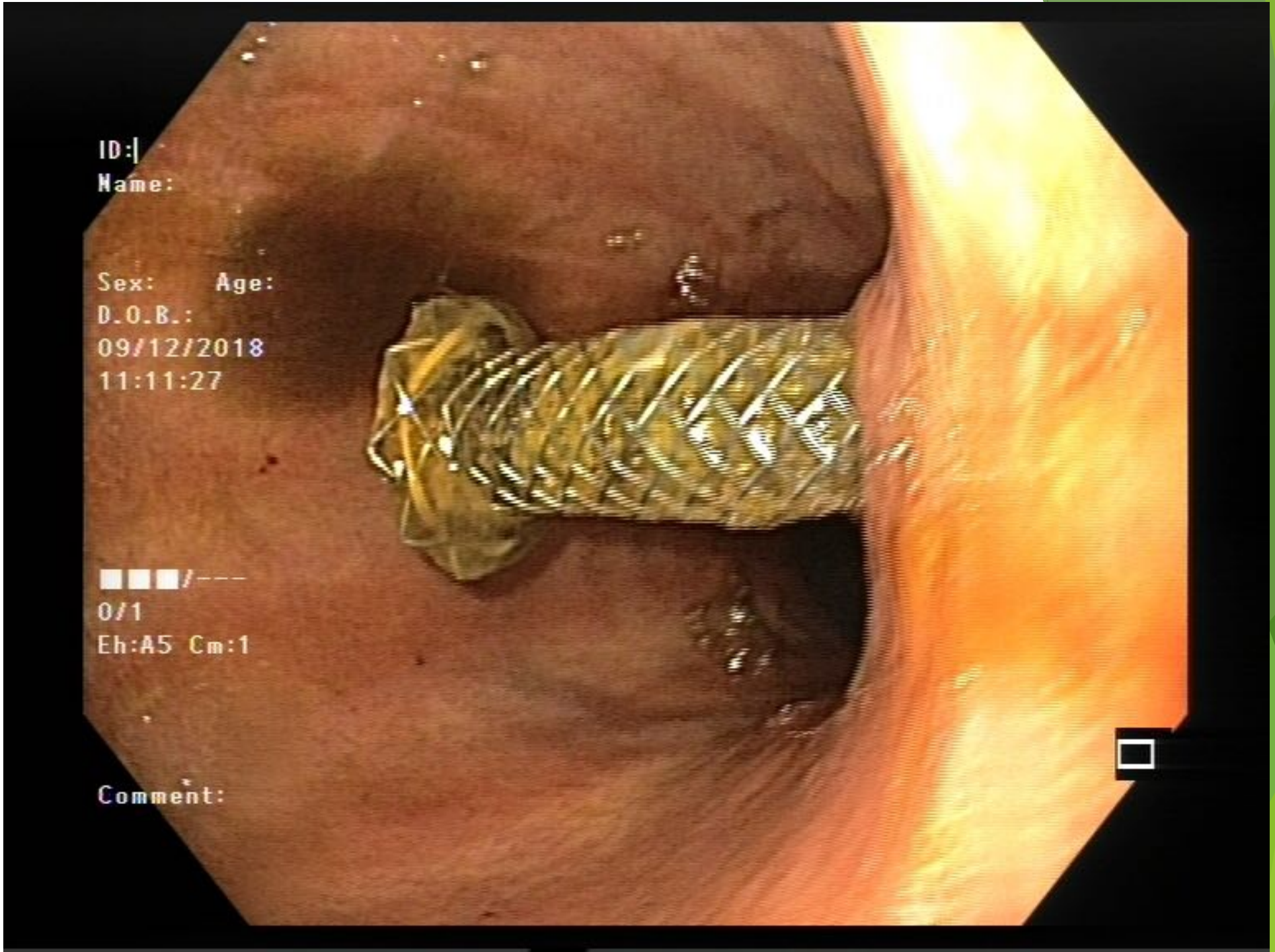
ID:
Name:
Sex: Age:
D.O.B.:
09/12/2018
11:11:27
■■■/---
0/1
Eh:A5 Cm:1
Comment:

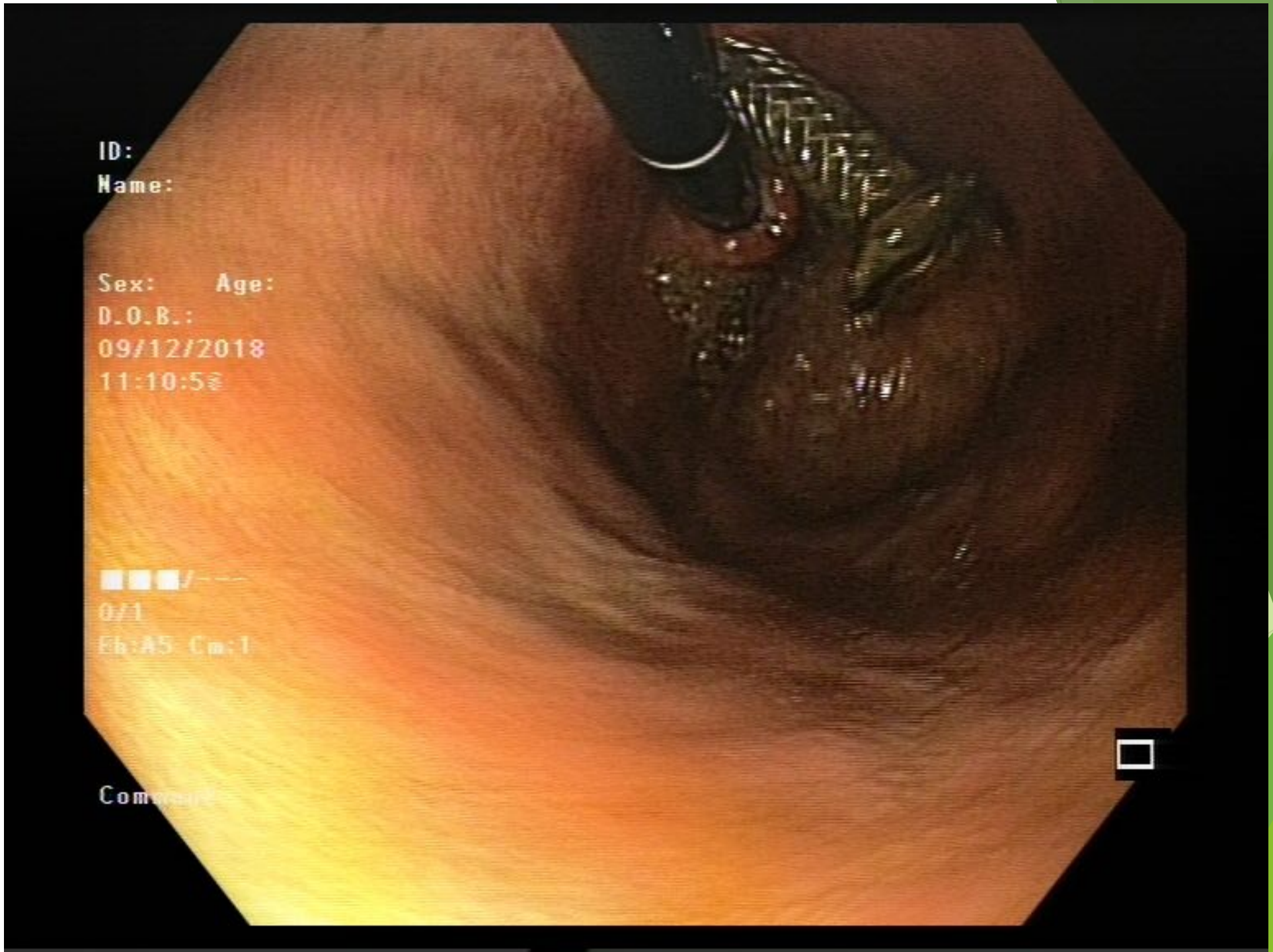
ID:
Name:
Sex: Age:
D.O.B.:
09/12/2018
11:10:5
0/1
Eh:A5 Cm:1

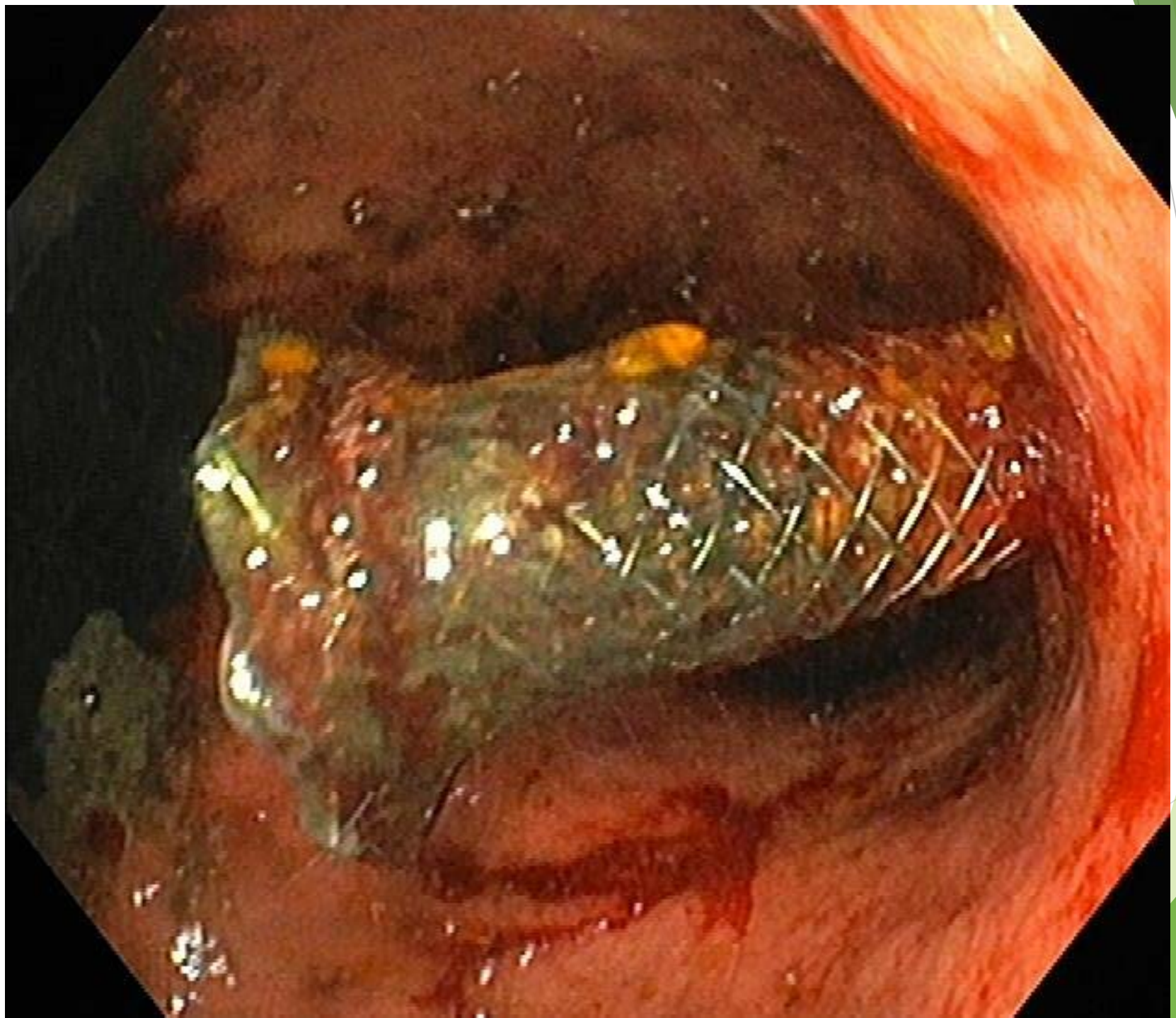

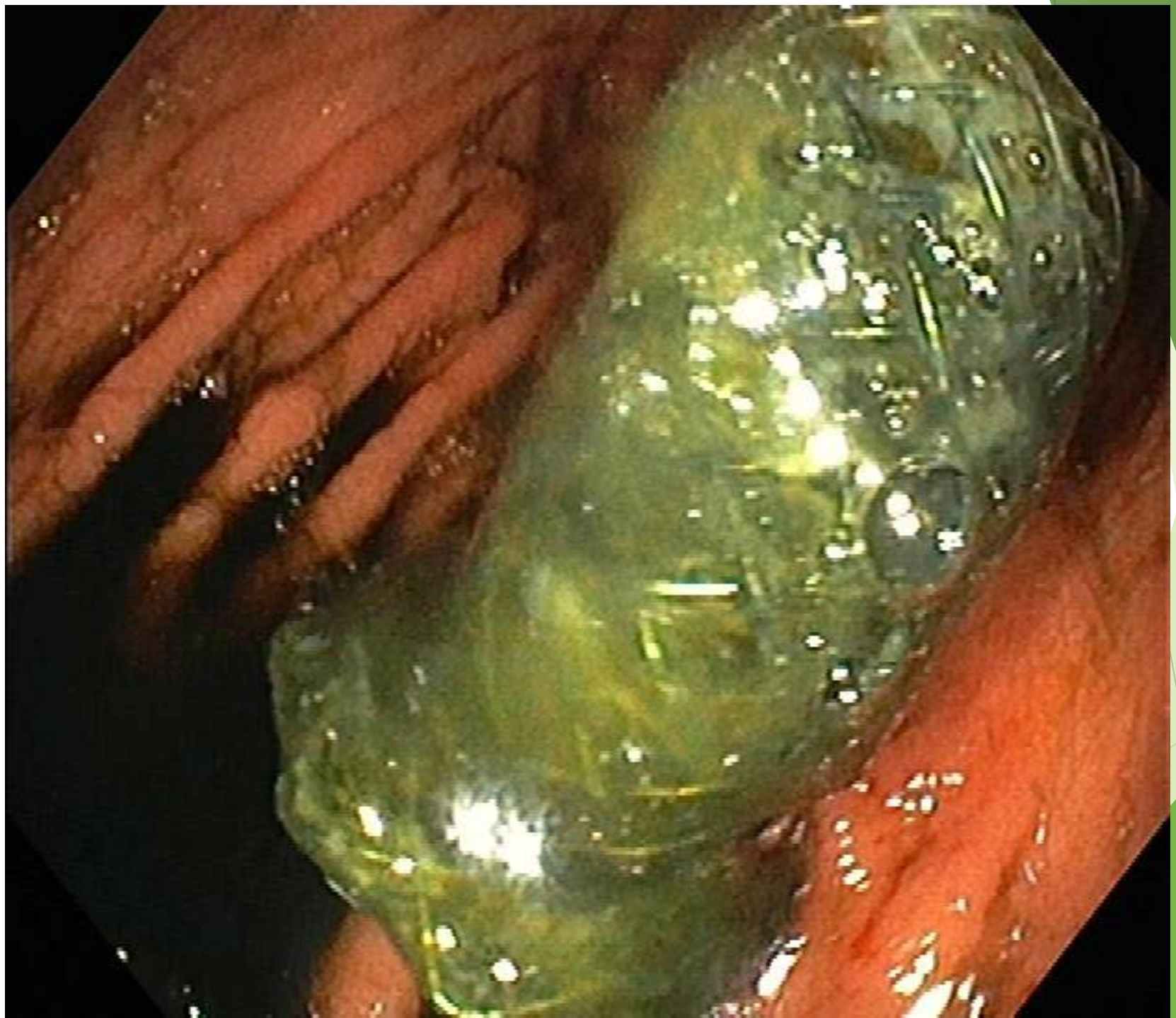



Extrahepatic Approach:
Choledochoduodenostomy

- **A,** EUS is utilized to access the extrahepatic bile duct with subsequent cholangiography and needle placement.
- **B,** The guidewire may be advanced into the intrahepatic bile ducts to provide a straight angle of access and stent delivery.
- **C** and **D,** The stent is advanced so that the distal tip rests within the biliary tree and the proximal end of the stent lies within the stomach or duodenum.

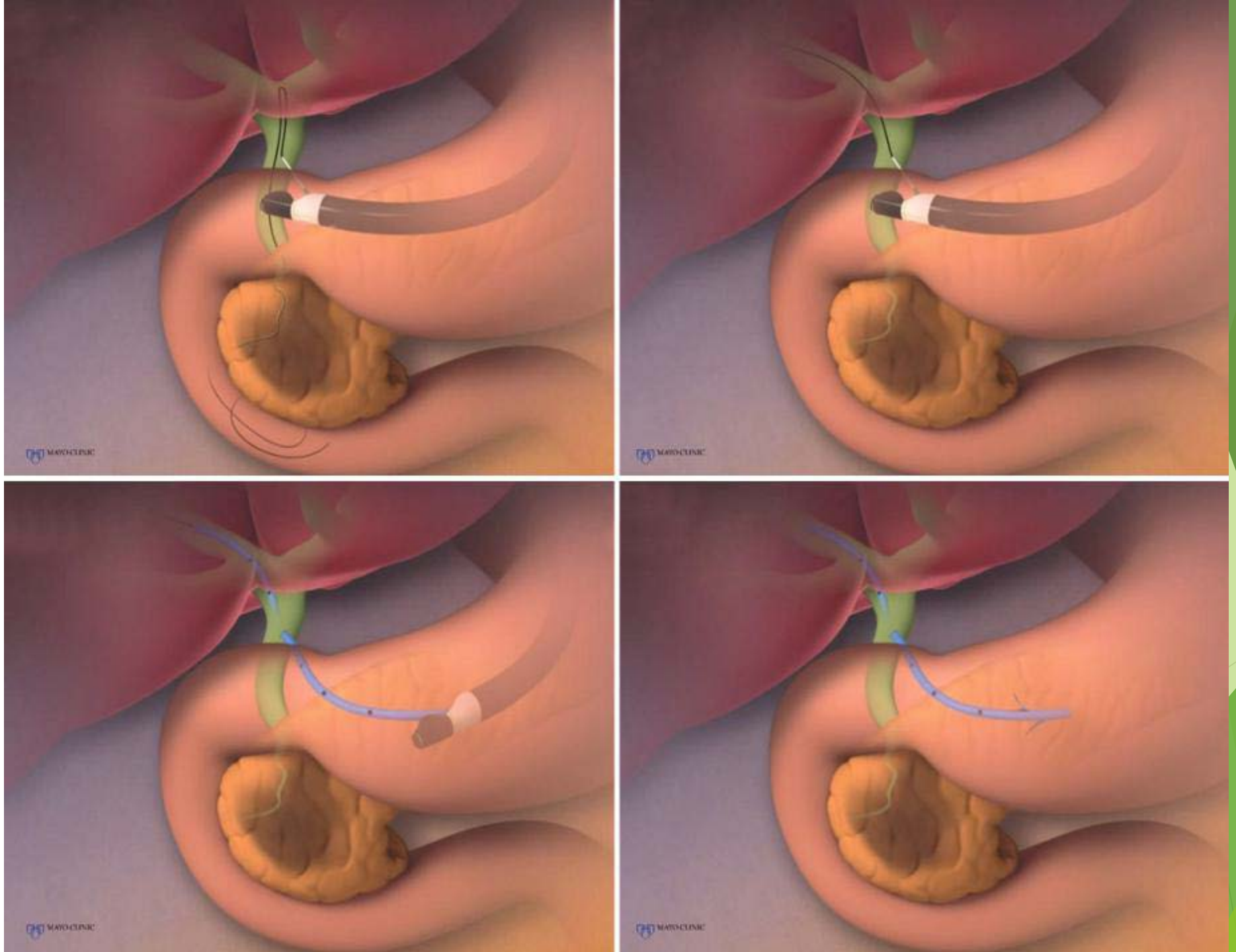

Choledochoduodenostomy. Curved access system tip (arrows) within the bile duct pointed toward the hilum.
Inset displays cholangiogram and selective guidewire advancement toward the liver.

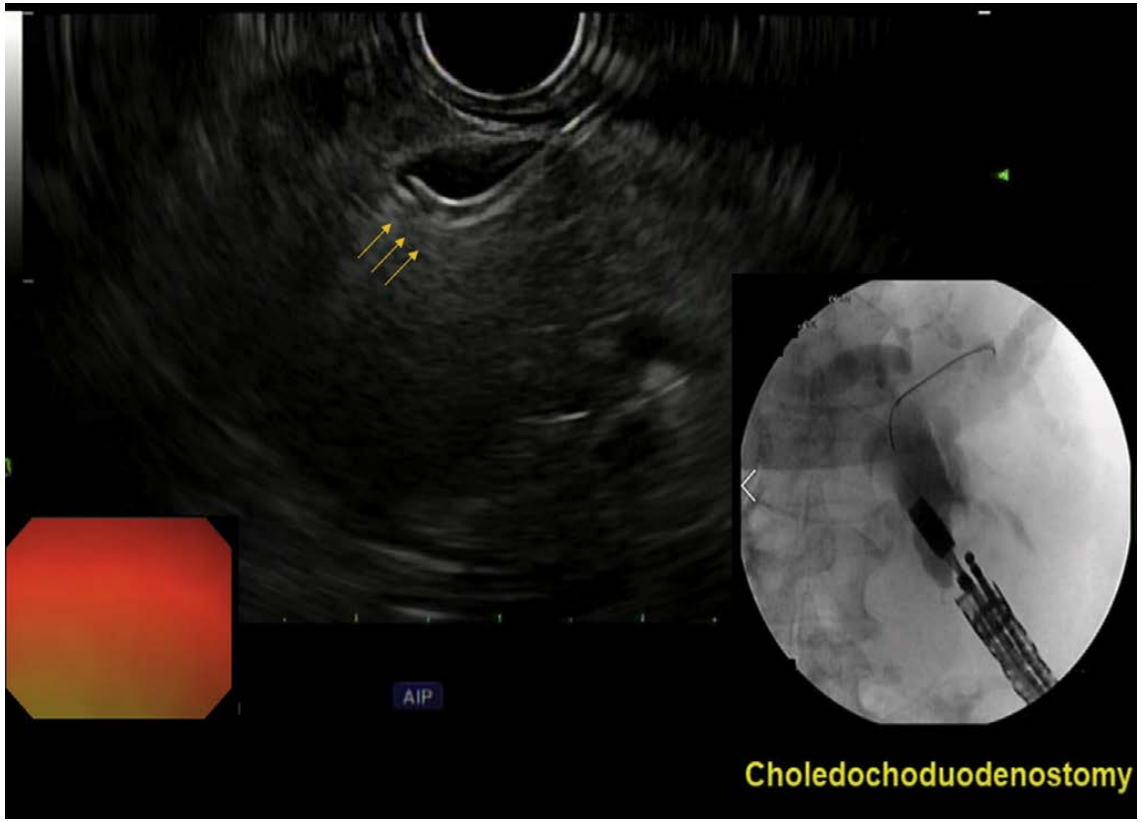

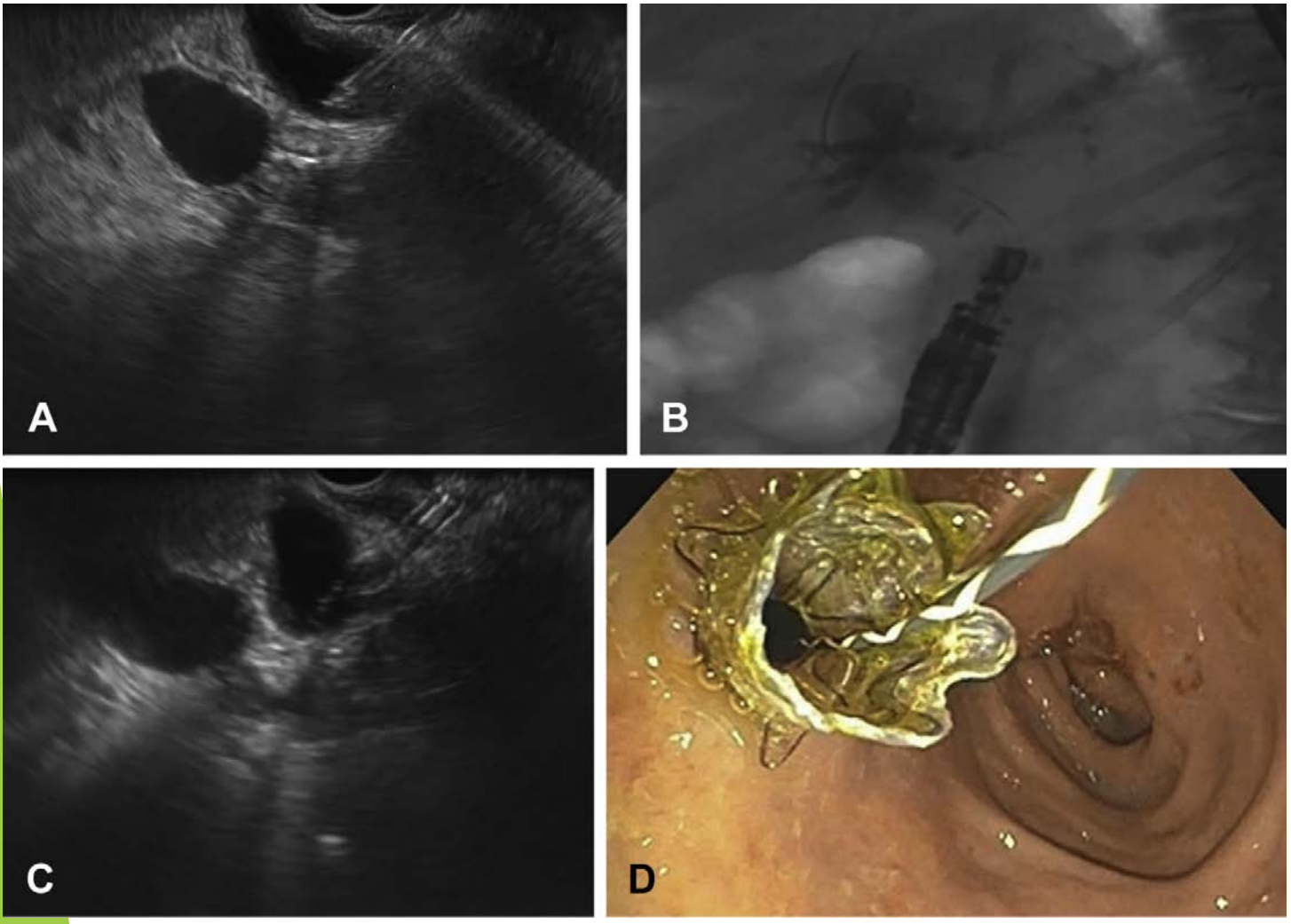

- Steps of EUS-guided biliary drainage.
- After puncturing the extrahepatic bile duct using a 19-gauge needle (A),
- a guidewire is inserted into the intrahepatic system (B).
- The transmural tract is balloon dilated (C),
- followed by insertion of a fully covered metal stent (D).

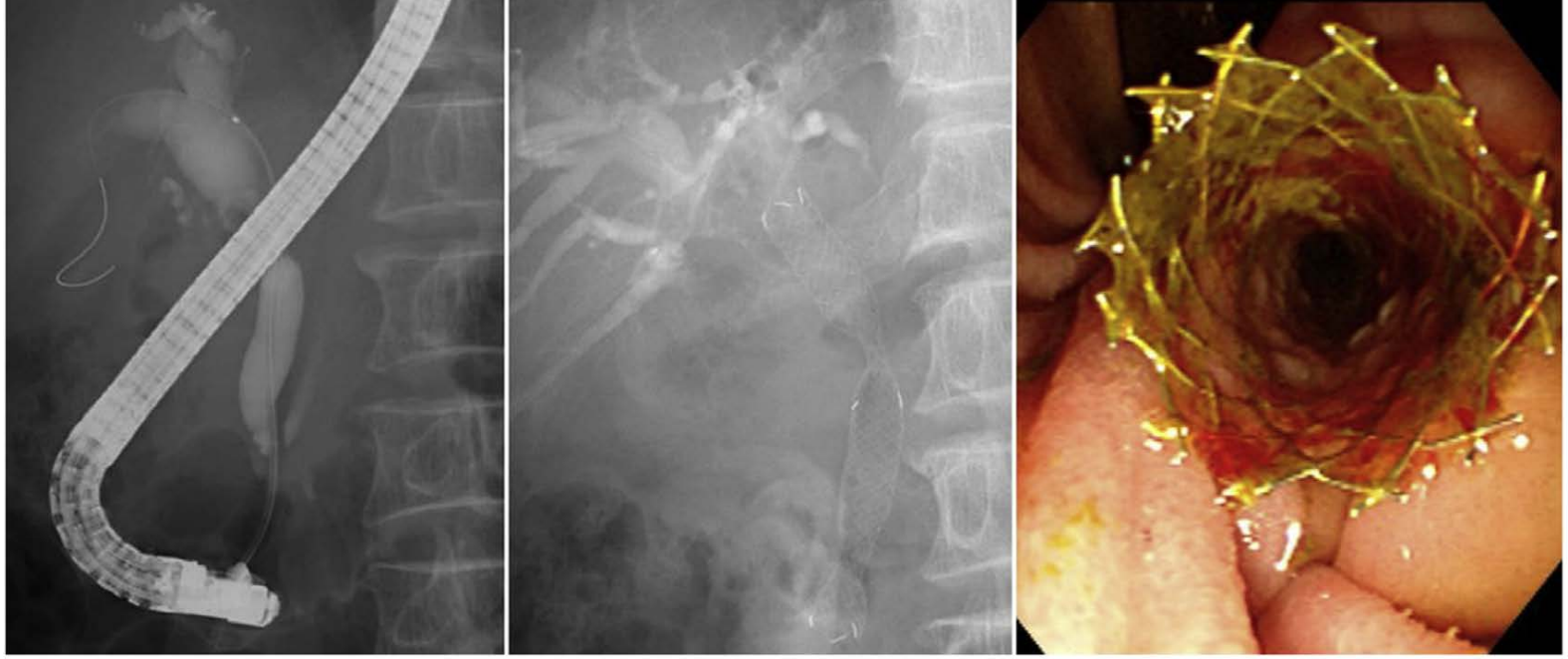

A

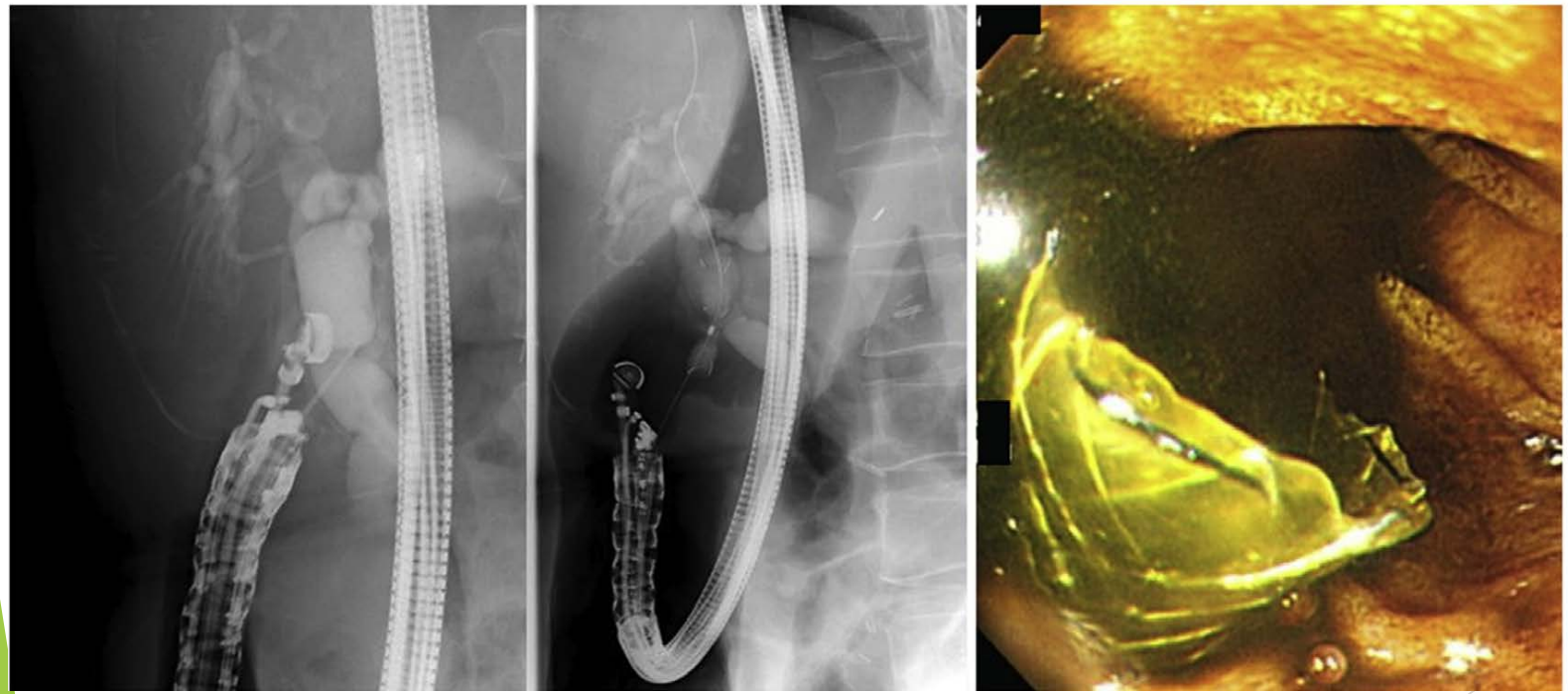

- A, ERCP with biliary stent placement.
- B, EUS-guided biliary drainage.

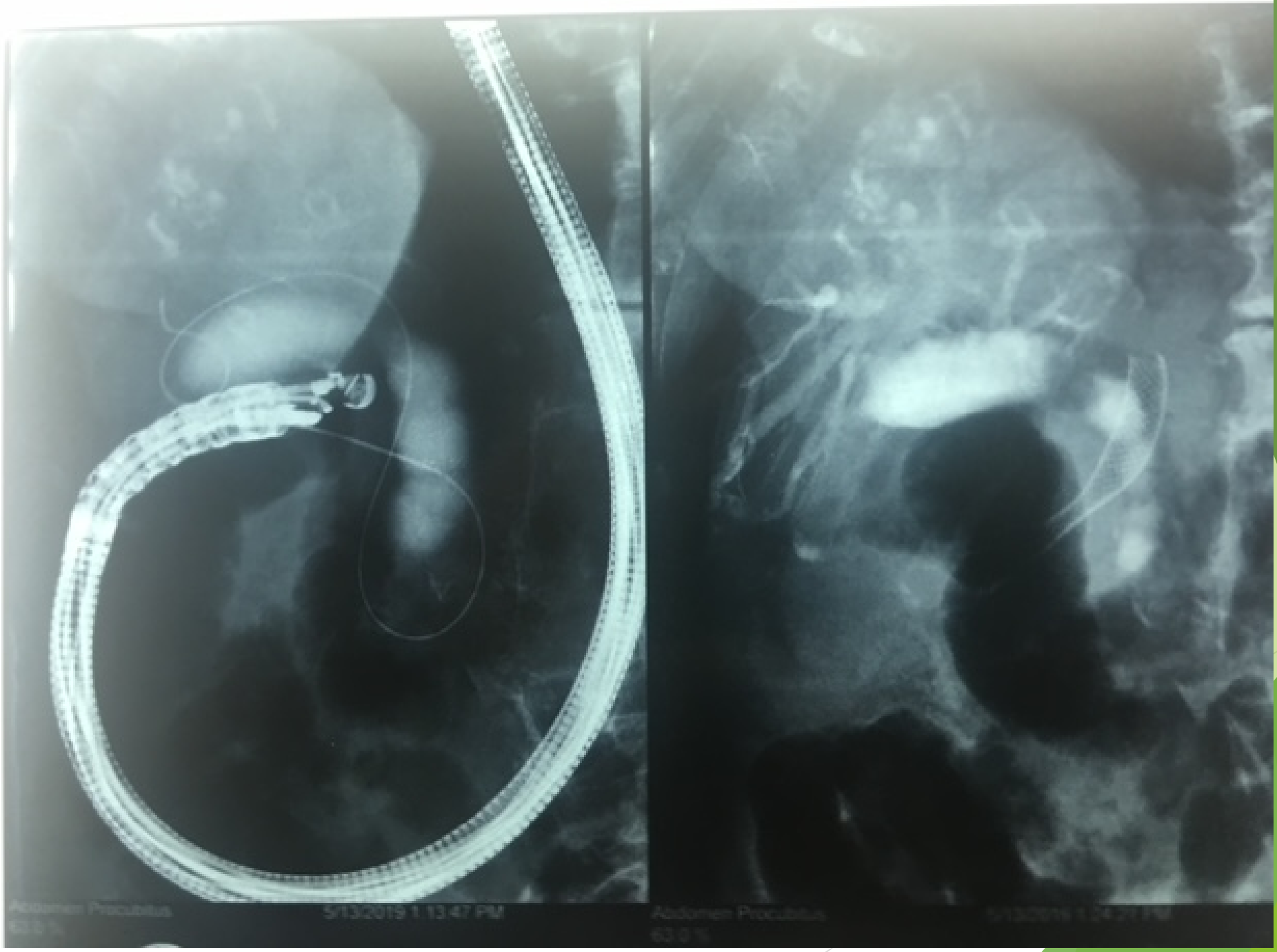
Abdomen Procubitus
5/13/2019 1:13:47 PM
Abdomen Procubitus


BADPAR AZARDOKHT
Female 73 year(s)
Tehran Clinic Dr amiryan
98/02/04

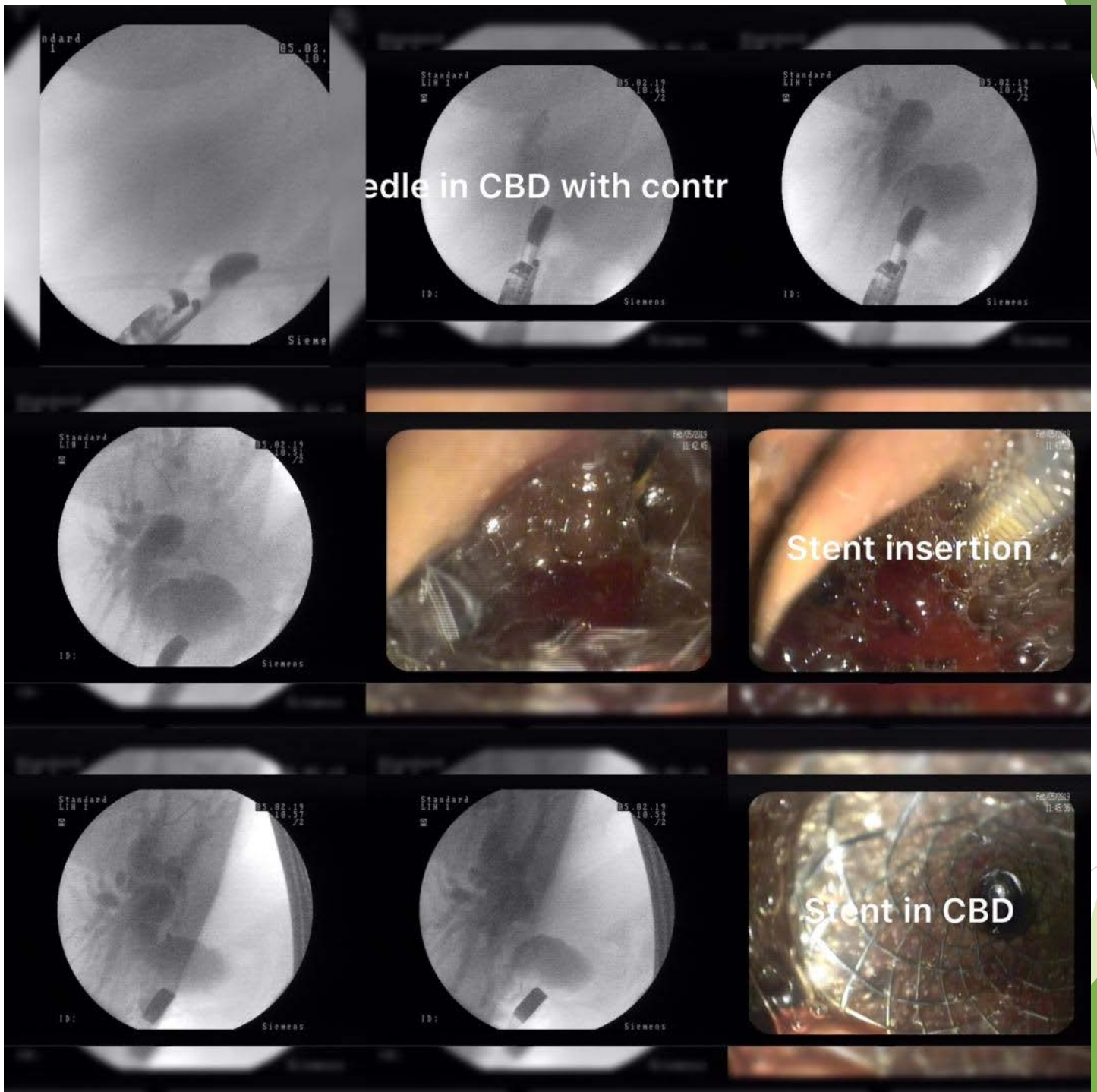
edle in CBD with contr
Stent insertion
Stent in CBD


0221.011907
PARS-HOSPITAL


0210221.011907
PARS-HOSPITAL


0221.011907
PARS-HOSPITAL

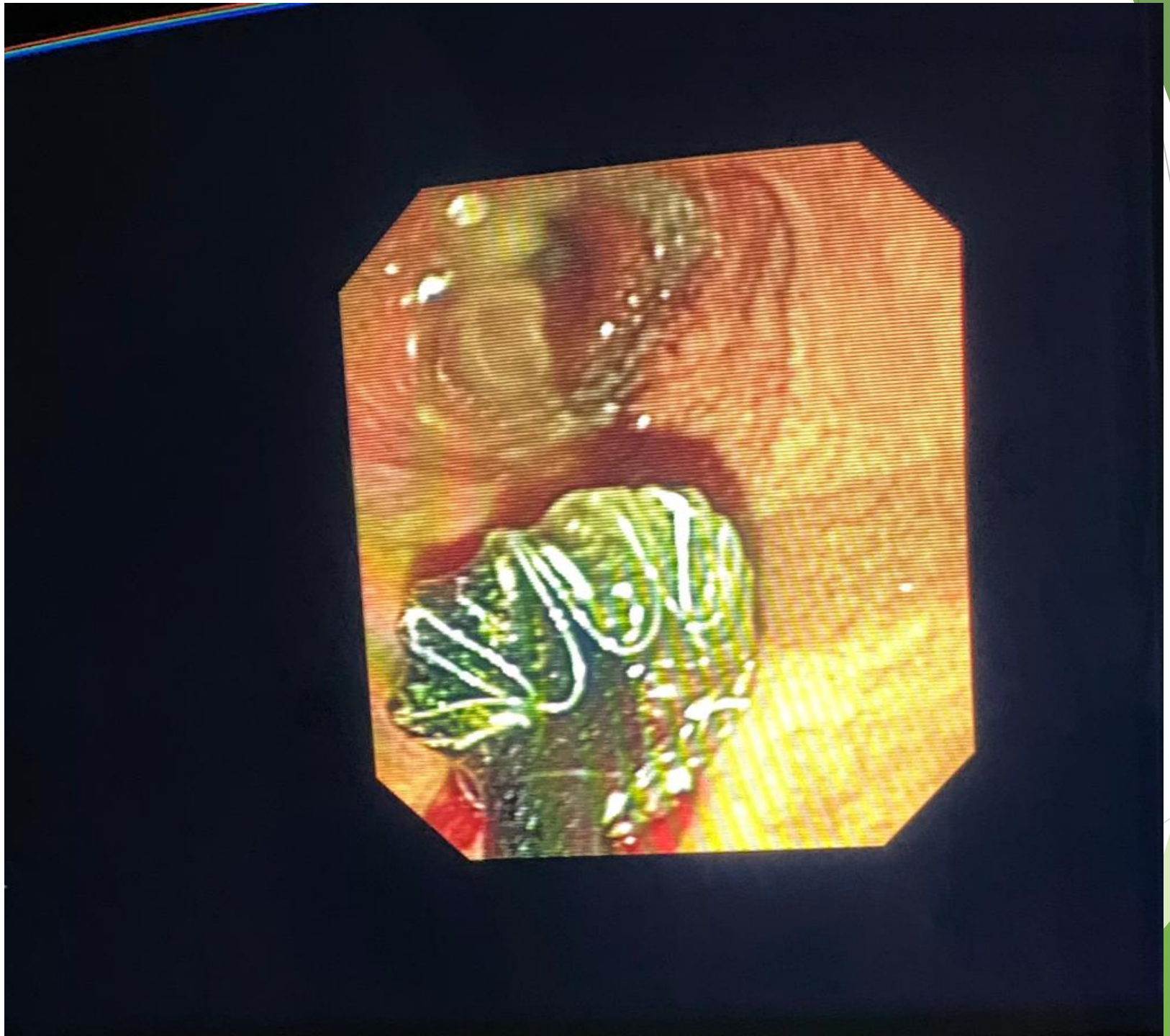

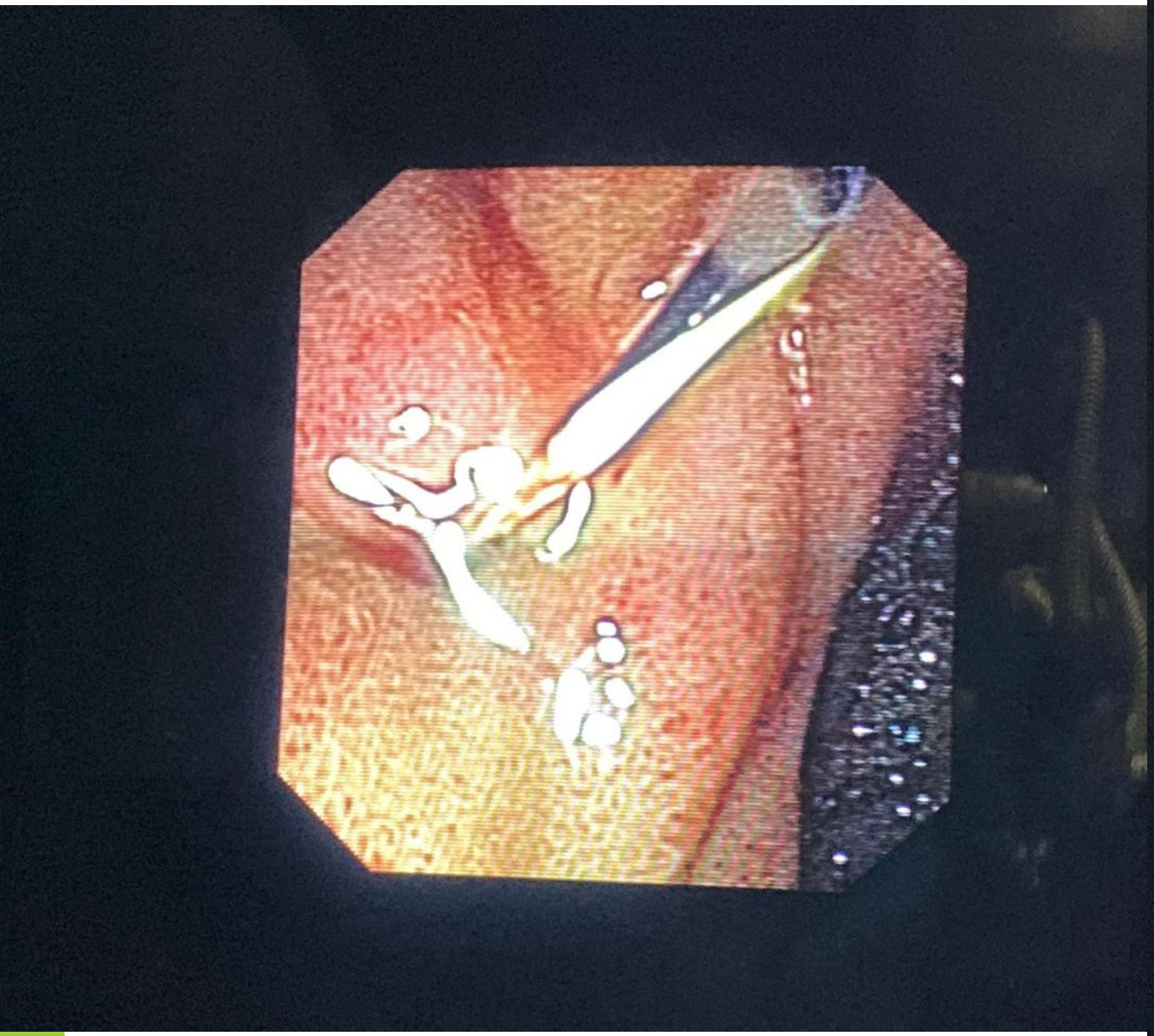



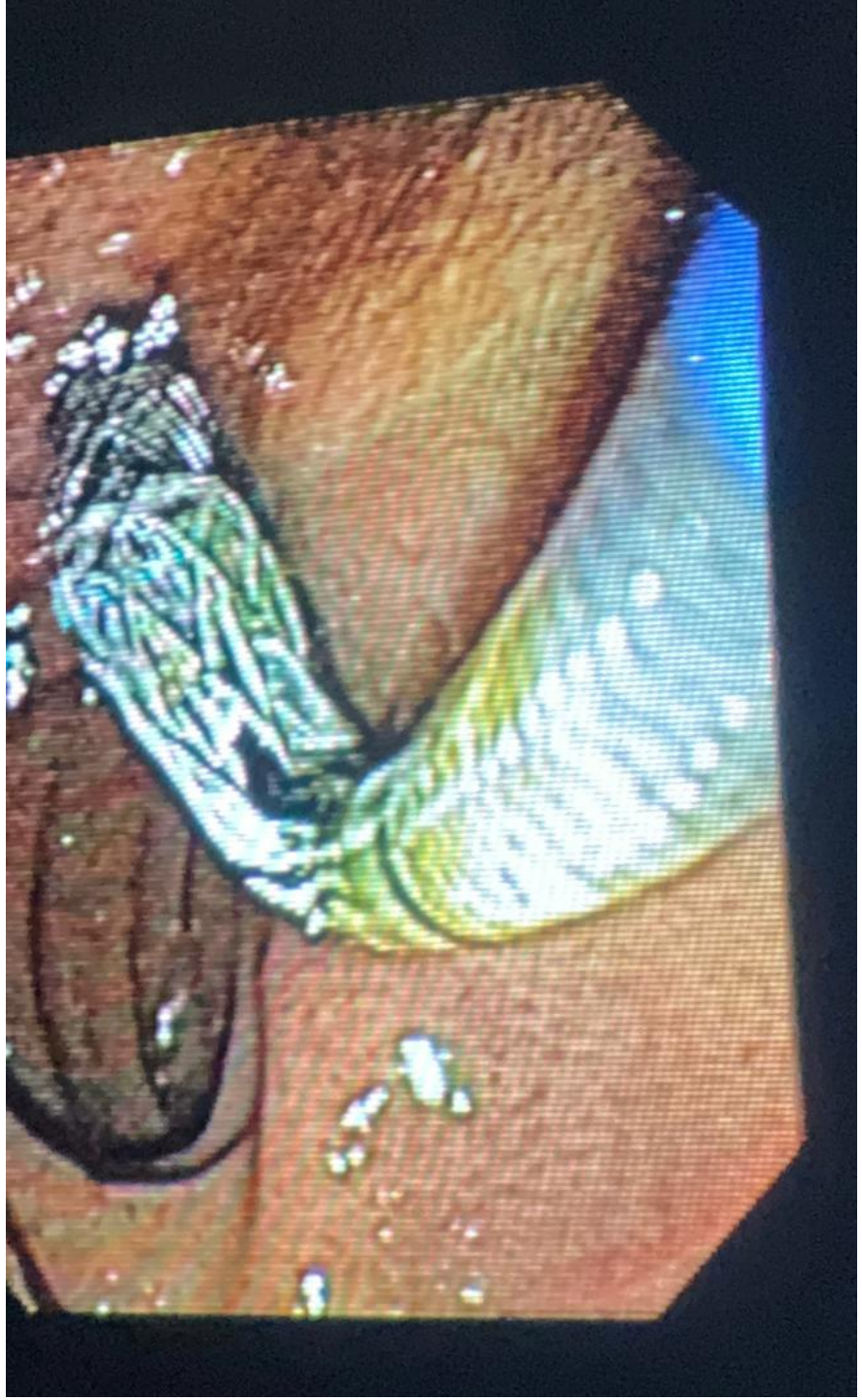



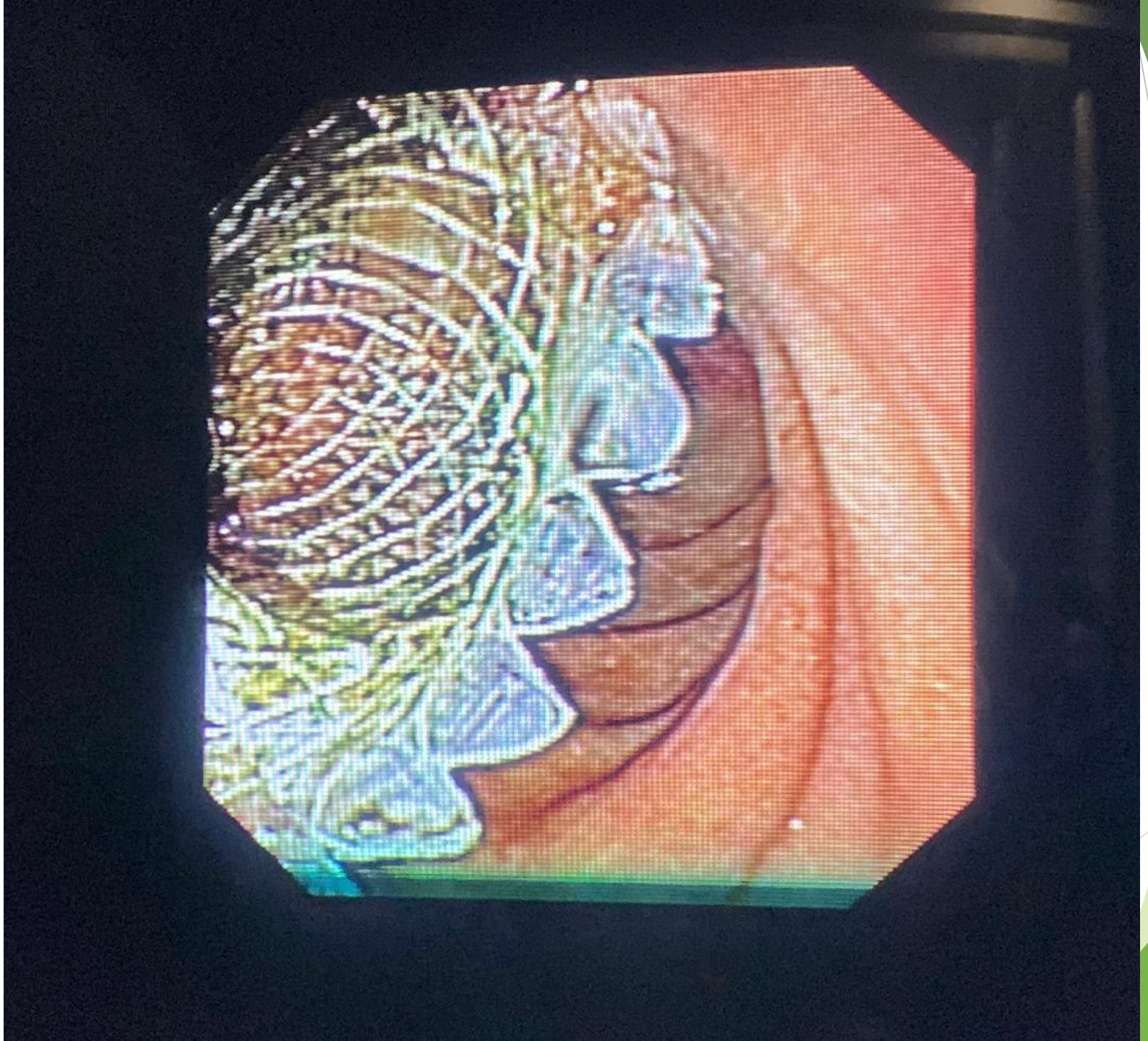

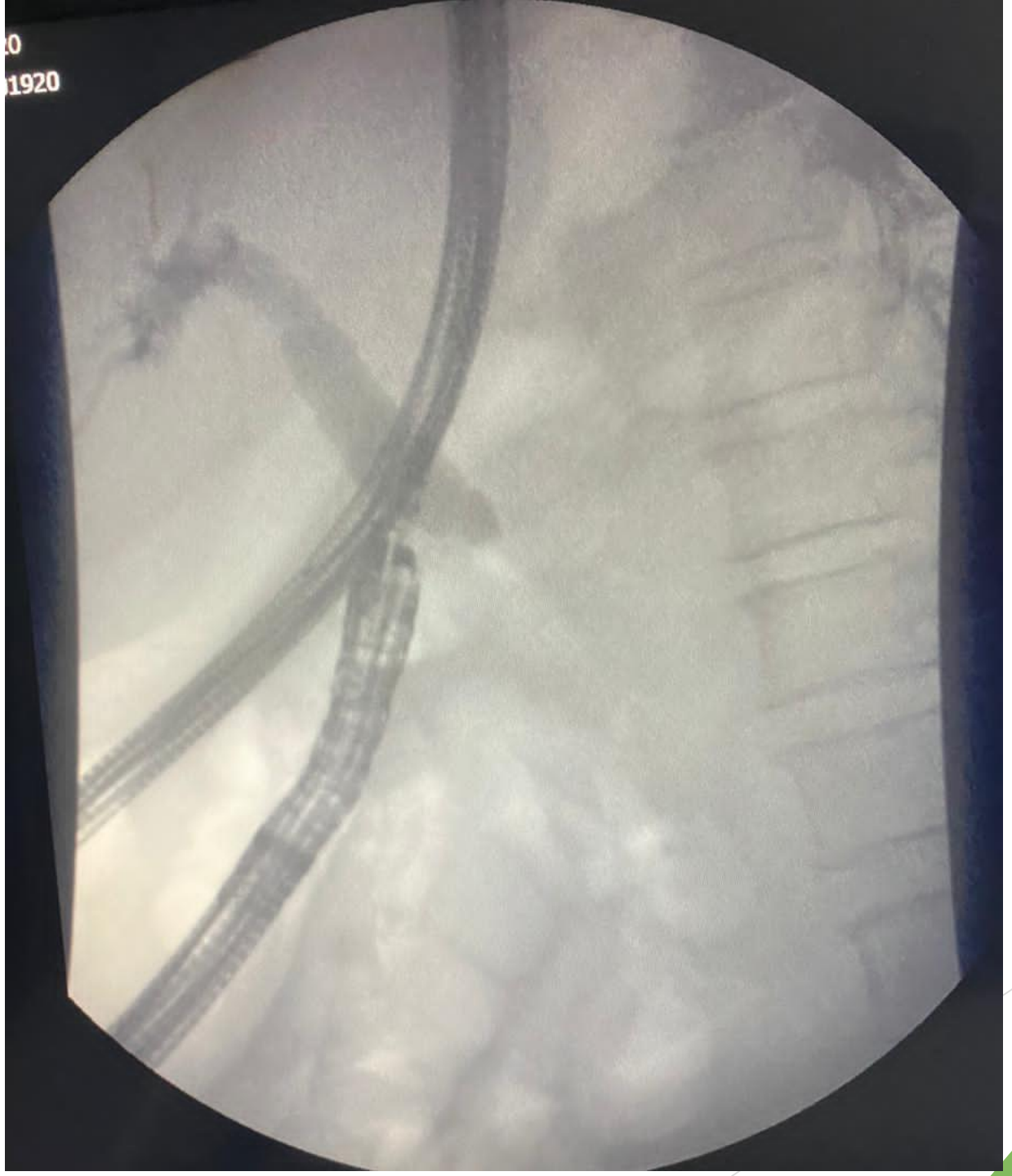
0
1920

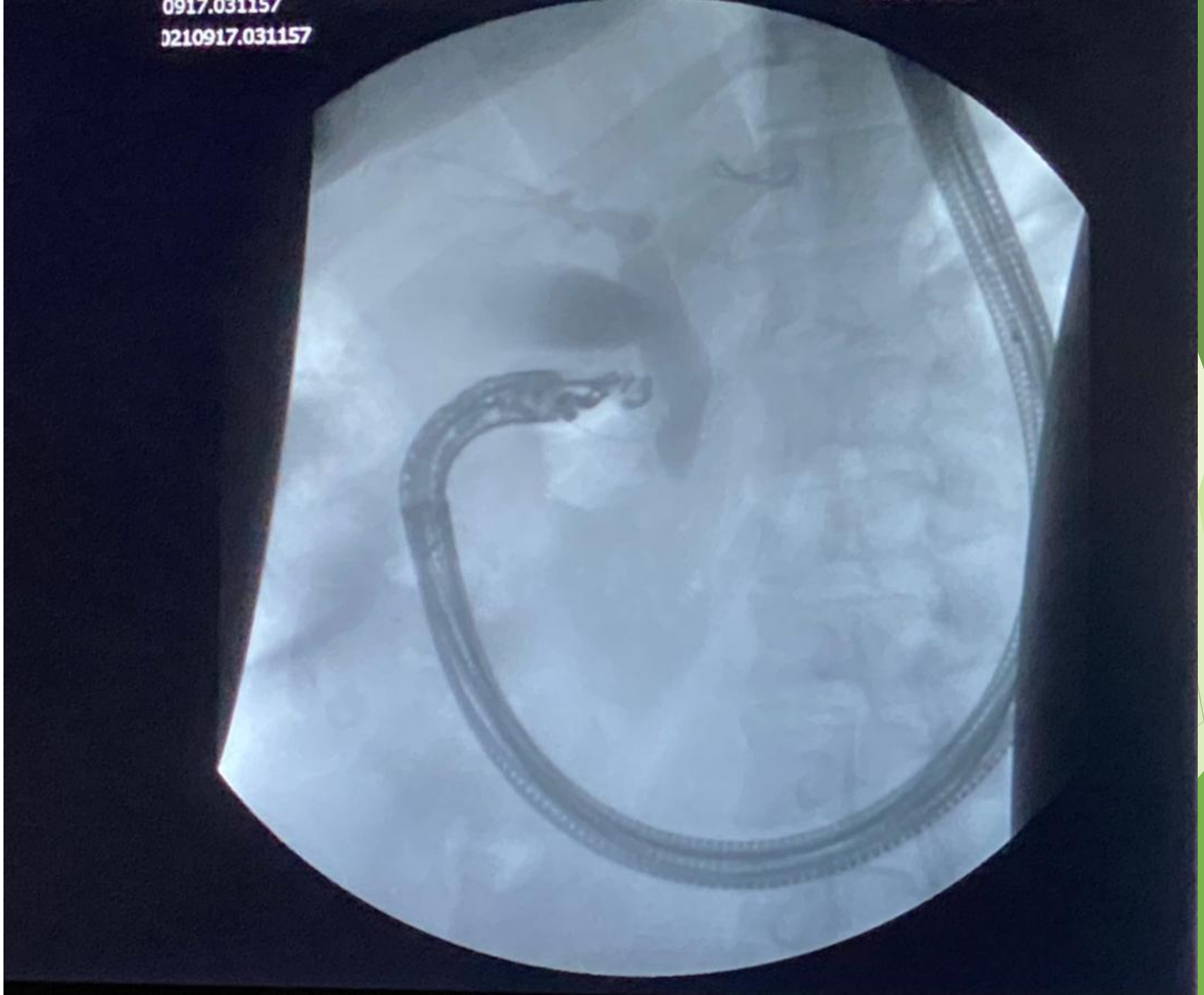
0917.031157
0210917.031157


1400-02-01...60Y


PARS-HOSPITAL

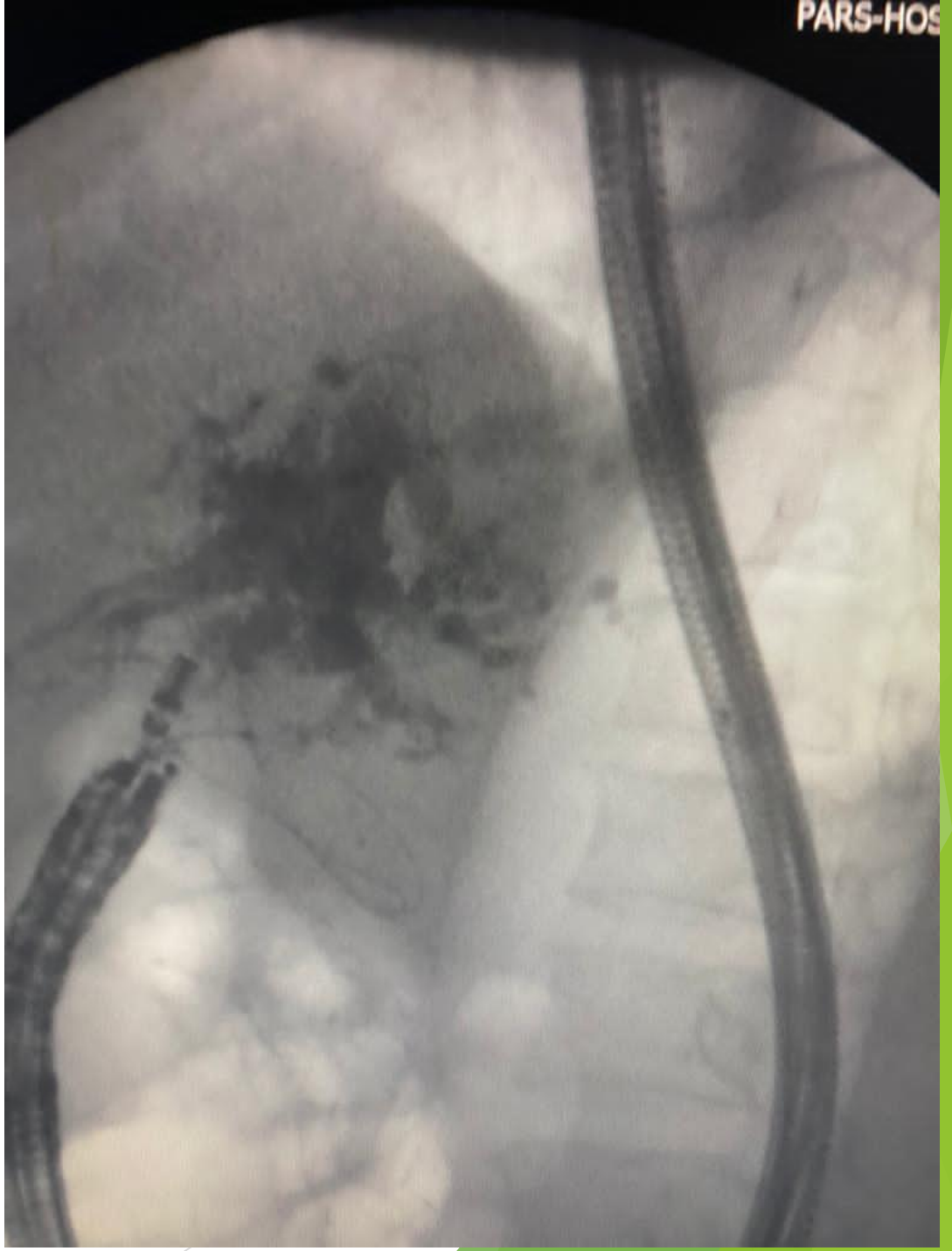
PARS-HOS

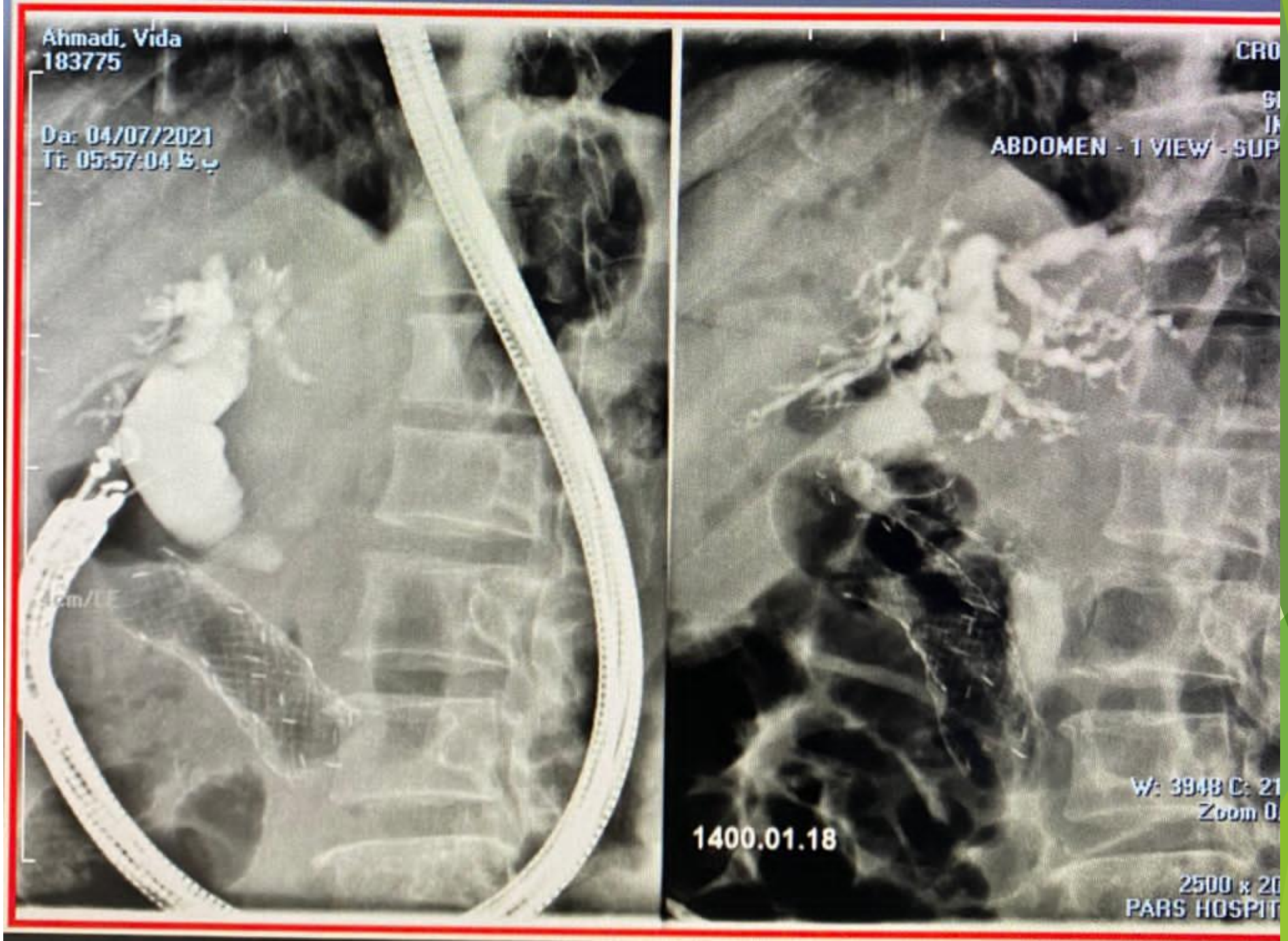
Ahmadi, Vida
183775
Da: 04/07/2021
Ti: 05:57:04
ABDOMEN - 1 VIEW - SUP
1400.01.18
PARS HOSPIT

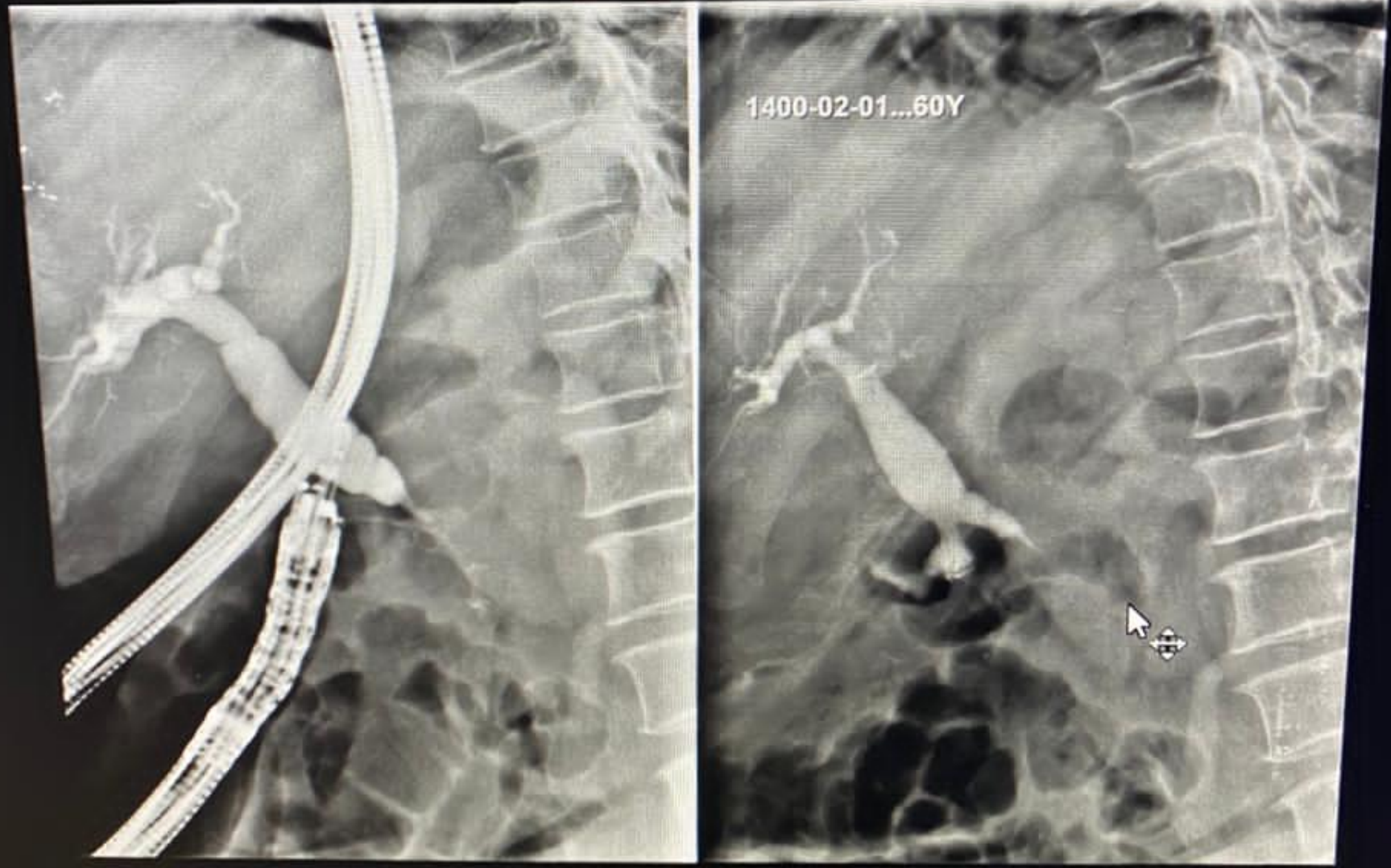
1400-02-01...60Y